

CLINICAL PRACTICE

Primary Retinal Detachment

Donald J. D'Amico, M.D.

This Journal feature begins with a case vignette highlighting a common clinical problem. Evidence supporting various strategies is then presented, followed by a review of formal guidelines, when they exist. The article ends with the author's clinical recommendations.

A 57-year old man noted flashing lights in his right eye, followed two days later by a cluster of dark floaters that mildly interfered with his vision. He initially ignored these symptoms, but over the course of the next week, he noted a progressive loss of the nasal visual field in that eye, beginning inferiorly and spreading superiorly, with an eventual striking loss of central acuity that prompted him to seek ophthalmologic evaluation. Examination of the fundus with the pupil dilated showed a retinal detachment involving the temporal retina, including the macula, with peripheral retinal tears at the 10:30 and 11:30 positions. How should his case be managed?

THE CLINICAL PROBLEM

From the Department of Ophthalmology, Weill Cornell Medical College and New York–Presbyterian Hospital, New York. Address reprint requests to Dr. D'Amico at the Department of Ophthalmology, Weill Cornell Medical College, New York–Presbyterian Hospital, 1305 York Ave., 11th Fl., New York, NY 10021, or at djdamico@med.cornell.edu.

N Engl J Med 2008;359:2346-54.

Copyright © 2008 Massachusetts Medical Society.

Rhegmatogenous retinal detachment, which refers to detachment due to round holes, tears, or breaks in the retina, is an important cause of visual symptoms and visual loss (Fig. 1). The development of rhegmatogenous detachment typically involves the convergence of three factors: posterior vitreous detachment, one or more full-thickness breaks in the retina, and the passage of fluid from the vitreous cavity through the retinal breaks into the potential subretinal space (Fig. 2). Vitreous currents from eye movements force fluid through these retinal breaks and progressively extend the retinal detachment.

Although typically an acute event, posterior vitreous detachment is a consequence of lifelong vitreous liquefaction and is highly age-dependent, occurring in less than 10% of patients younger than 60 years of age but in 27% of patients in the seventh decade of life and 63% of those in the eighth decade of life¹; it occurs earlier in patients who have myopia.² In most cases, patients perceive floaters of various types, including newly mobile normal vitreous structures, occasional vitreous hemorrhage (at times severe), and pigmentary debris, and 22 to 44% of patients see flashing lights.²⁻⁴

Retinal breaks occur in 11 to 15% of patients.²⁻⁴ These breaks develop in areas of strong vitreoretinal adhesion, typically along retinal vessels, or in patients with certain predisposing conditions, notably lattice retinal degeneration (Fig. 1 in the Supplementary Appendix, available with the full text of this article at www.nejm.org), which is characterized by a focal peripheral area of retinal thinning, often with atrophic holes, variable pigmentation, and strong vitreous adhesions. Lattice lesions are present in approximately 8% of patients⁵ and are more common among patients with high degrees of myopia. Although posterior vitreous detachment, myopia, and lattice retinal degeneration are all relatively common, rhegmatogenous retinal detachment is rare. Population-based studies show that the annual incidence is approximately 12.6 cases per 100,000 persons, or 17.9 per 100,000 if detachments after cataract extraction (a common risk factor) are included.⁶ Longitudinal studies suggest that a new tear or detachment occurs in approximately 1% of patients with lattice retinal degeneration.⁷

The retina is normally maintained in its attached position by many factors, but most importantly by a continued physiologic outward movement of fluid across the retinal pigment epithelium into the choroid.⁸ This retinal pigment epithelium pump is overwhelmed by fluid passing through a retinal break when retinal detachment develops. Most patients present when the loss of side vision occurs, but some present only after central vision is reduced because of detachment of the macula.⁶ Although both detachments that involve the macula and those that do not involve the macula preoperatively are amenable to surgery, intervention before macular detachment improves the visual prognosis significantly.

Primary retinal detachment refers to rhegmatogenous detachment that occurs in a previously uninvolved phakic eye (i.e., an eye in which the crystalline lens is present) without any complicating factors (e.g., underlying diabetic retinopathy or penetrating trauma) or that occurs after cataract surgery; the latter occurs most commonly in patients with pseudophakic eyes (i.e., an eye with an artificial intraocular lens) but may also occur in patients with aphakic eyes (i.e., an eye with no lens). Although detachments after cataract surgery have many distinguishing features (a predisposition to multiple breaks, tiny breaks, far peripheral location of breaks, and greater extent and higher incidence of macular detachment on presentation),^{9,10} the similarities to detachments from other causes are more substantial, and detachments after cataract surgery are appropriately discussed in the context of primary detachment.

Recurrent retinal detachment reflects a failure of the repair of the primary detachment. It may result from unsuccessful closure of the original breaks in the retina, the occurrence of new or missed retinal breaks, or more ominously, the overgrowth of the retina by membranes and scar tissue (a condition known as proliferative vitreoretinopathy; Fig. 2 in the Supplementary Appendix). Although a retina with proliferative vitreoretinopathy may often be reattached with the use of advanced techniques, the chance for successful reattachment and visual recovery is much lower than it is with primary reattachment.¹¹⁻¹³

STRATEGIES AND EVIDENCE

PREOPERATIVE EVALUATION

Patients with new symptoms of flashing lights or floaters or with loss of central or side vision should

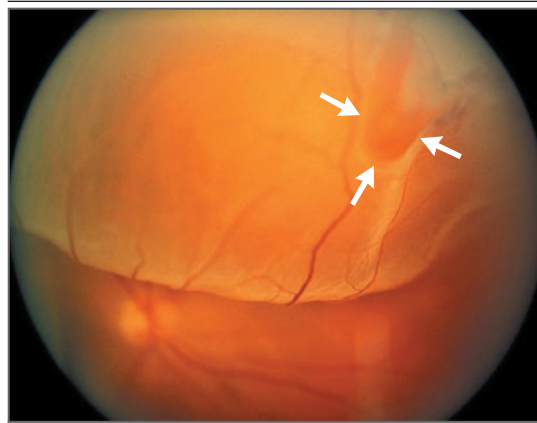


Figure 1. Primary Rhegmatogenous Retinal Detachment with a Horseshoe Tear.

The photograph of the fundus shows the highly elevated superior retina with a characteristic horseshoe break (arrows); this horseshoe configuration is the result of the anterior direction of the tearing force.

be evaluated promptly (ideally, within a few days if flashes or floaters are the only symptoms and within 24 hours if there is any visual loss) to determine whether posterior vitreous detachment, retinal breaks or detachment, or other problems are present. If a retinal detachment is found, evaluation includes dilation of the pupil for examination of the fundus with the use of an indirect ophthalmoscope, with scleral depression to detect all retinal breaks. Because retinal breaks, lattice degeneration, and retinal detachment are often bilateral, the other eye must also be carefully examined. If retinal breaks without detachment are detected, they may be treated on an outpatient basis with retinopexy, which consists of cryotherapy or laser treatment applied to the retinal break and retinal pigment epithelium in order to induce the formation of a scar (Fig. 3 in the Supplementary Appendix).

SURGERY

The three principal methods for reattachment of the retina are scleral buckling, vitrectomy, and pneumatic retinopexy.

Scleral Buckling Surgery

Scleral buckling surgery is an extraocular approach that indents the eye wall to restore contact with the detached retina (Fig. 3). Typically, a piece of silicone of appropriate configuration is positioned with sutures on the external sclera under the retinal breaks; tightening the sutures over the buck-

le indents the eye wall.¹⁴ Although the vitreous remains attached to the retinal breaks, the shortening of the distance to the underlying retinal pigment epithelium restores contact; reattachment may be further enhanced by the drainage of subretinal fluid, although this maneuver is not necessary in all cases. The individual breaks are treated with cryotherapy or laser therapy to ensure permanent closure.

Scleral buckling results in high rates of successful reattachment and substantial recovery of vision. In a recent study involving 190 eyes, the success rate (defined in all studies as anatomical reattachment regardless of visual acuity) for a single operation was 89%.¹⁵ In another recent study, involving 672 eyes treated by a single surgeon, the success rate for a single operation was 81% for the 354 phakic eyes and 73% for the 318 eyes in which the retinal detachment had occurred after cataract surgery.¹⁶ Additional surgery after failure of the initial operation resulted in a final reattachment rate of 96%; the rate did not differ significantly between surgery for phakic eyes and surgery for eyes in which detachment had occurred after cataract surgery.¹⁶ The outcomes with respect to visual acuity varied depending on the preoperative visual acuity and on whether there was macular detachment. Final visual acuity was 20/40 or better in 51.3% of eyes, 20/50 to 20/100 in 17.3%, and 20/200 or worse in 31.4%. In a subgroup analysis, final visual acuity was 20/40 or better in 78% of the eyes in which the macula was not detached, as compared with only 28% of the eyes with preoperative macular detachment.

Patients in whom the macula is not detached on presentation must undergo prompt, occasionally emergency, surgery, with the goal of preventing macular detachment. Several studies have shown that the duration of macular detachment (measured from the reported time of the loss of central visual acuity) is inversely related to final visual acuity. One recent study showed that there was a rapid drop in final visual acuity if the macula was detached for more than 6 days.¹⁷ Another study showed that the outcomes with respect to visual acuity were best when the duration of macular detachment was less than 7 days, but there was no difference in the outcome between patients with macular detachment of 0 to 3 days' duration and those with macular detachment of 4 to 7 days' duration, supporting the clinical prac-

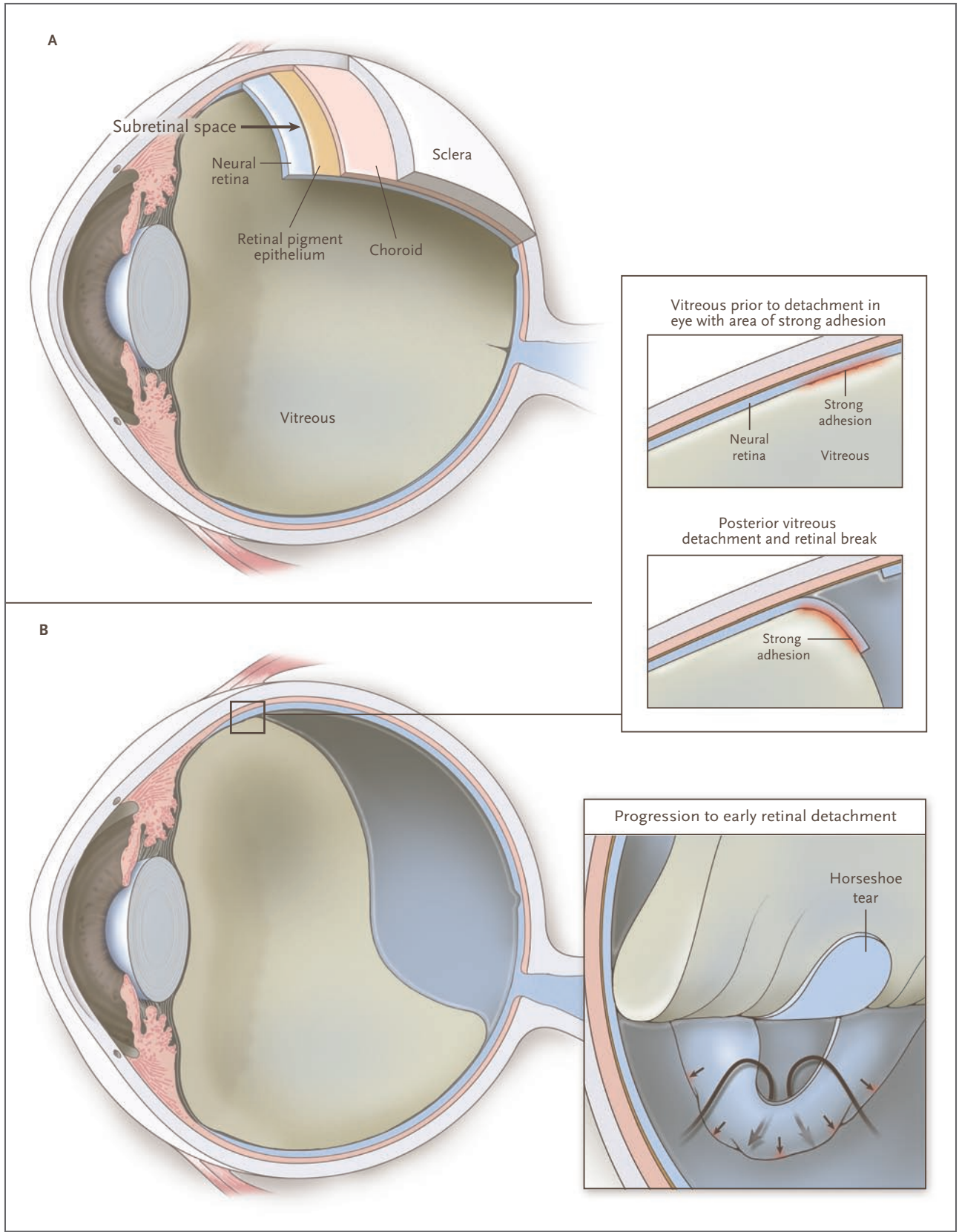
Figure 2 (facing page). Ocular Anatomy, Posterior Vitreous Detachment, Retinal Tears, and Retinal Detachment.

A cutaway view of the eye (Panel A) shows the vitreous, neural retina, retinal pigment epithelium, choroid, and sclera. The space between the neural retina and the retinal pigment epithelium is known clinically as the subretinal space and is the plane of retinal detachment. Posterior vitreous detachment (Panel B) is part of the process of aging. Whereas at younger ages, there is a continuous connection between the vitreous and the retina, with advanced age, the vitreous progressively separates from the retina. The separation begins at the posterior pole and rapidly progresses until it reaches the anterior retinal periphery, where the anatomical connection is unyielding (top inset). Posterior vitreous detachment may result in retinal tears (top inset). A tear is most likely in an area with a strong vitreoretinal adhesion that impedes separation. Fluid from the vitreous cavity may pass through the tear into the subretinal space (bottom inset), resulting in progressive retinal detachment. Some tears seal spontaneously in an unpredictable fashion and do not result in detachment; they may be observed in certain eyes on peripheral retinal examination.

tice of performing prompt, but usually not emergency, surgery.¹⁸

Recurrent detachment is an important complication after scleral buckling (or any reattachment surgery) and is often successfully managed with additional surgery. The development of proliferative vitreoretinopathy is the primary cause of failure of reattachment despite multiple interventions.¹³ Other complications include an increase in the degree of myopia, which is very common, and the formation of macular epiretinal membranes (Fig. 4 in the Supplementary Appendix), which occurs in a small percentage of cases. Infrequent complications¹⁴ (occurring in less than 5% of cases) include cystoid macular edema, retinal breaks, intraocular dislocation of an implanted lens, vitreous and choroidal hemorrhage, loss of vitreous during suturing or drainage, diplopia, glaucoma, choroidal detachment, cataract formation, eyelid malpositions, and late extrusion or infection of the buckle. Retinal vascular occlusion, anterior segment ischemia, and endophthalmitis are extremely rare.

Postoperative assessment with the use of optical coherence tomography, a technique commonly used for examination of the retina, in which a laser scans the macula and produces an optical histologic section, has shown persistent micro-



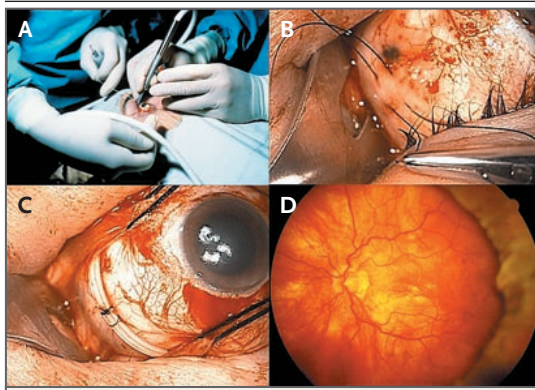


Figure 3. Scleral Buckling Surgery for Retinal Detachment.

With the use of the indirect ophthalmoscope for precise visualization, each break is treated with cryotherapy. A localizing pen mark is also made on the sclera for each retinal break by similar ophthalmoscopic visualization with scleral depression (Panel A [right eye]). A buckling element is selected that has a size and shape sufficient to indent each break. Sutures are placed to affix the buckle to the external sclera with substantial indentation (Panel B [right eye]). A buckle may be affixed in an equatorial or radial orientation, may encircle the eye under the rectus muscles and be tightened like a belt (as shown in Panel C [right eye]), or may be arrayed in many combinations. The retina is reattached after the encircling scleral buckle has been secured and subretinal fluid has been drained (Panel D [left eye]). The indentation (seen at right) induced by scleral buckling reduces vitreous traction on the retinal break; the retinopexy seals the break by inducing a localized peripheral scar (not shown).

detachment in the fovea in a substantial percentage of cases in which the macula was detached preoperatively^{19,20} and in a minority of cases in which the macula was not detached,²¹ even when ophthalmoscopic examination shows that the retina appears to have been successfully reattached (Fig. 5 in the Supplementary Appendix). This submacular fluid requires many months to resolve and is associated with impaired visual recovery.

Vitrectomy

Vitrectomy (Fig. 4) is an intraocular approach that relieves traction by removing the vitreous attached to the retinal breaks, permitting reapproximation to the retinal pigment epithelium, where the breaks are permanently closed with retinopexy.²² A bubble containing sulfur hexafluoride gas, perfluoropropane gas, or (rarely in cases of primary detachment) silicone oil is placed in the vitreous cavity; the gas bubble gradually disappears over the

course of 1 to 4 weeks, depending on the concentration used, whereas oil requires surgical removal. Gas or oil tamponade spans and closes the retinal break and permits the retinal pigment epithelium pump to maintain attachment of the retina until the retinopexy scar develops. The patient must maintain a specified head position for several 1-hour periods throughout the day until the gas bubble dissolves; the optimal position is determined by the location of the breaks and the effect of gravity on the bubble. The patient's head should also be positioned so that prolonged contact of the bubble with the crystalline lens is minimized, since such contact may result in the development of a cataract.²²

Vitrectomy may also increase the risk of a cataract through other mechanisms. Removal of the vitreous and the intraoperative infusion of fluids produce some measurable changes in the lens, which increase directly with the age of the patient, although clinically significant changes occur in only a minority of patients, even among patients older than 50 years of age.²³ The additional use of intravitreal gas increases the risk of measurable changes in the lens in older patients²³; one study showed substantial progression of a cataract after vitrectomy in 79% of patients who were 50 years of age or older but in only 7% of younger patients.²⁴ Patients who are being treated with intraocular gas must also avoid airplane travel,²⁵ as well as inhalation anesthesia with nitrous oxide,²⁶ owing to a harmful elevation of intraocular pressure while a bubble is present.

Vitrectomy avoids some of the complications associated with scleral buckling, such as diplopia, choroidal detachment, perforation of the sclera, abnormalities in the eyelid, and, of course, late extrusion and infection of the buckle, but it carries higher risks of several other complications, including cataract formation in phakic eyes, glaucoma and other problems with tamponade, and new retinal breaks.²²

Most of the data regarding reattachment with vitrectomy are derived from studies of pseudophakic eyes. In a study involving 275 pseudophakic eyes with detachment treated by vitrectomy, the single-operation success rate was 88%, and the final success rate (including reoperations) was 96%; the median visual acuity improved from 20/300 to 20/40.²⁷ A recent prospective study of 100 pseudophakic eyes showed a single-operation

success rate of 92%, with a final success rate of 97%; mean visual acuity was substantially improved, from 20/200 to 20/50, with better absolute acuity in the subgroup without preoperative macular detachment.²⁸

Pneumatic Retinopexy

Pneumatic retinopexy (Fig. 5), a procedure performed in the ophthalmologist's office,³⁰ draws on the ability of a small bubble of pure sulfur hexafluoride or perfluoropropane,³¹ which is injected intravitreally, to expand over the course of 1 or 2 days through absorption of tissue nitrogen and other gases. With appropriate positioning of the head, retinal breaks are closed by the bubble, allowing the retinal pigment epithelium pump to reattach the retina. Gradual elution of gas from the eye coupled with permanent closure of the break by retinopexy leaves the retina reattached.

Pneumatic retinopexy has several advantages over the other procedures: it is less invasive, is associated with fewer complications, and is less costly; however, it is not suitable as a treatment for every detachment owing to practical limitations in the ability to close breaks by head-positioning with an intraocular gas bubble. The original studies of pneumatic retinopexy involved treatment of primary detachments with small breaks that were restricted to the superior two thirds of the fundus.^{30,32} In a study of 103 eyes, the initial pneumatic retinopexy was successful in 75% of phakic eyes and 67% of pseudophakic eyes, with a final success rate (after various additional interventions) of 99% in all eyes at 6 months of follow-up.³² In the subgroup of patients in whom the duration of macular detachment was fewer than 14 days, the postoperative acuity was 20/50 or better in 80% of the eyes.

In a study of 302 consecutive cases treated by a single surgeon,³³ the single-operation success rate was 68%, and the final reattachment rate was 95% after scleral buckling, vitrectomy, or both were performed for recurrent detachment. The author noted that the success rate was 63% in a subgroup of cases treated according to the originally described pneumatic retinopexy technique but that this rate was increased to 91% by the addition of 360-degree peripheral-laser therapy. Eighty-five percent of eyes without macular detachment and 66% of eyes with macular detachment had final visual acuity of 20/40 or better.

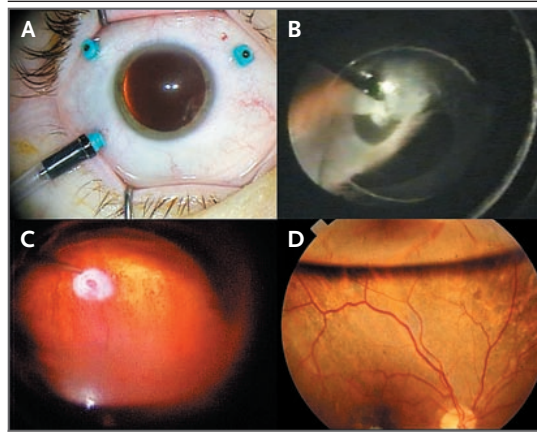


Figure 4. Three-Port Pars Plana Vitrectomy for Rhegmatogenous Retinal Detachment.

Panel A shows transconjunctival 25-gauge pars plana vitrectomy. The two superior ports permit introduction of a suction-cutter (vitrector), a fiberoptic endoilluminator, and other instruments in conjunction with continuous infusion of fluid through the third port. The vitreous cavity is viewed with an operating microscope and specialized viewing systems. Panel B shows vitrectomy to remove anterior vitreous traction to a horseshoe tear. The circular outline of the intraocular lens is visible in this pseudophakic eye. Panel C shows a panoramic view of endolaser treatment for a peripheral retinal break in the air-filled eye after removal of subretinal fluid for intraoperative retinal reattachment. Panel D shows intraocular tamponade (visible superiorly) by means of air, long-acting gas, or silicone oil to maintain closure of the break in association with appropriate positioning of the patient's head postoperatively until permanent retinopexy scarring develops. Gases elute spontaneously from the eye, but silicone oil requires subsequent surgical removal.

The results of more recent studies^{34,35} confirm these findings, with a single-operation success rate of 65% and 77% and a final success rate of 99% in both studies. In the most recent study, final visual acuity was 20/50 or better in 81% of the eyes without macular detachment and in 74% of the eyes with macular detachment, with similar outcomes for phakic eyes and eyes in which detachment occurred after cataract surgery.³⁵

Studies show that a single failed pneumatic retinopexy does not reduce the chances for success with subsequent surgery.^{33,36} Failure is most common when there are missed or new retinal breaks but may also be due to the development of proliferative vitreoretinopathy, which is reported in 3.3 to 10% of cases. Other uncommon complications include the development of epiretinal

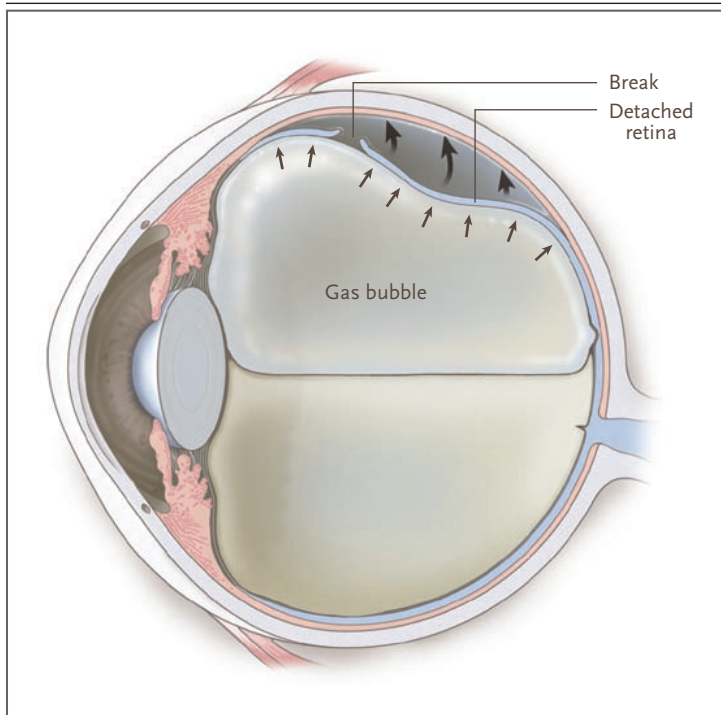


Figure 5. Outpatient Pneumatic Retinopexy.

A cutaway view of the eye is shown. After treatment of retinal breaks by retinopexy, with the use of an indirect ophthalmoscope for visualization of the breaks, a small intravitreal gas bubble is injected and expands to span and close the breaks in the detached retina (small arrows) in association with appropriate positioning of the patient's head. Reattachment of the retina occurs through physiologic resorption of subretinal fluid (large arrows). Gradual elution of gas from the eye leaves the retina reattached, with the retinal breaks permanently closed by the retinopexy scar. (Reprinted from D'Amico.²⁹)

membranes (in a small percentage of cases), cataracts (which are extremely rare), and endophthalmitis (described in isolated case reports).

COMPARISON OF PROCEDURES

There is a paucity of randomized trials comparing scleral buckling, vitrectomy, and pneumatic retinopexy as treatment for primary retinal detachment. Furthermore, major advances³⁷⁻⁴¹ in techniques for vitrectomy (e.g., refined and miniaturized instrumentation and panoramic visualization) are not reflected in published trials, perhaps resulting in an underestimation of its success. One randomized, multicenter trial comparing pneumatic retinopexy with scleral buckling³² in 198 eyes showed no significant difference in single-operation success rates (73% and 82%, respectively) or final success rates (99% and 98%, respectively) at 6 months. However, visual acuity was better in the group that received treatment

with pneumatic retinopexy; among patients who presented with macular detachment of short duration, final visual acuity was 20/50 or better in 80% of those who were treated with pneumatic retinopexy, as compared with 56% of those who were treated with scleral buckling.

In a randomized trial comparing vitrectomy and scleral buckling for primary detachment in 150 pseudophakic eyes treated by a single surgeon, the single-operation success rate was significantly higher with vitrectomy than with buckling (94% vs. 83%); final outcomes with respect to visual acuity were equivalent.⁴² Another randomized trial, involving 50 pseudophakic eyes treated by a single surgeon, showed no significant difference between vitrectomy and scleral buckling in the single-operation success rate (84% and 76%, respectively) but showed a significant benefit of vitrectomy with respect to visual acuity.⁴³ A recent trial involving multiple surgeons, in which patients were randomly assigned to treatment with vitrectomy or scleral buckling, showed that in 225 eyes with primary detachment after cataract surgery, there were no significant differences in single-operation success rates (63% with vitrectomy and 68% with scleral buckling) or final success rates (92% and 85%, respectively) or in the outcomes with respect to visual acuity.⁴⁴ Microdetachment in the fovea appears to be less likely to persist after vitrectomy than after scleral buckling.⁴⁵

In a multicenter, randomized trial involving 634 eyes with primary detachment (369 phakic eyes and 265 eyes with retinal detachment after cataract surgery), vitrectomy was compared with scleral buckling.^{46,47} In the cohort with phakic eyes, the single-operation success rate was identical for the two interventions (64%), as was the final success rate (97%), but the outcomes with respect to visual acuity were better with buckling, owing to the progression of cataracts in the vitrectomy group. However, interpretation of the results is complicated by the fact that many patients who had been randomly assigned to the vitrectomy group actually underwent combination surgery that included scleral buckling, possibly inflating the rate of complications ascribed to vitrectomy.

AREA OF UNCERTAINTY

With few randomized trials available, the selection of scleral buckling, vitrectomy, or (for the restricted indications mentioned above) pneumatic retinopexy for primary retinal detachment remains

subjective.⁴⁸⁻⁵² Data from case series suggest that primary detachments in phakic eyes with complexity exceeding the original indications for pneumatic retinopexy may be treated successfully with scleral buckling or vitrectomy,⁴⁹⁻⁵¹ whereas vitrectomy appears to be preferable for corresponding detachments in pseudophakic eyes.^{28,42,53,54}

GUIDELINES

Neither the American Academy of Ophthalmology nor the Retina Society has published formal guidelines for selecting the optimal surgical procedure for the repair of retinal detachments.

CONCLUSIONS AND RECOMMENDATIONS

The patient described in the vignette presents with classic symptoms of primary retinal detachment, including flashing lights and floaters followed by a progressive loss of the visual field. My preference would be to treat the patient with a pneumatic retinopexy, given that the breaks are in the superior two thirds of the fundus and that this proce-

dures can be performed in the physician's office, with lower costs and less risk of complications than with the other procedures; this approach has approximately a 75% chance of restoring visual acuity to 20/50 or better. However, the patient must understand that a subsequent procedure may be needed. I would alternatively consider a vitrectomy with gas tamponade and retinopexy. Although scleral buckling is also an effective option for this patient, I regard the potential complications associated with scleral buckling to be of greater concern than the risk of a cataract with vitrectomy, given that the rate of success associated with cataract surgery, if a cataract should develop as a result of vitrectomy, is high. My recommendations would be the same if the patient's eye was pseudophakic. Regardless of the intervention selected for a patient with primary retinal detachment, there is a high probability of reattachment and visual improvement with current treatments.

Dr. D'Amico reports receiving speaking fees from Alcon and a departmental grant from Research to Prevent Blindness; he also reports being the current president of the Retina Society. No other potential conflict of interest relevant to this article was reported.

An audio version of this article is available at www.nejm.org.

REFERENCES

1. Foos RY, Wheeler NC. Vitreoretinal juncture: synchysis senilis and posterior vitreous detachment. *Ophthalmology* 1982; 89:1502-12.
2. Jaffe NS. Complications of acute posterior vitreous detachment. *Arch Ophthalmol* 1968;79:568-71.
3. Tasman WS. Posterior vitreous detachment and peripheral retinal breaks. *Trans Am Acad Ophthalmol Otolaryngol* 1968; 72:217-24.
4. Lindner B. Acute posterior vitreous detachment and its retinal complications: a clinical biomicroscopic study. *Acta Ophthalmol Suppl* 1966;87:1-108.
5. Byer NE. Lattice degeneration of the retina. *Surv Ophthalmol* 1979;23:213-48.
6. Rowe JA, Erie JC, Baratz KH, et al. Retinal detachment in Olmsted County, Minnesota, 1976 through 1995. *Ophthalmology* 1999;106:154-9.
7. Byer NE. Changes in and prognosis of lattice degeneration of the retina. *Trans Am Acad Ophthalmol Otolaryngol* 1974; 78:OP114-OP125.
8. Pederson JE, MacLellan HM. Experimental retinal detachment. I. Effect of subretinal fluid composition on reabsorption rate and intraocular pressure. *Arch Ophthalmol* 1982;100:1150-4.
9. Lois N, Wong D. Pseudophakic retinal detachment. *Surv Ophthalmol* 2003;48: 467-87.
10. Christensen U, Villumsen J. Prognosis of pseudophakic retinal detachment. *J Cataract Refract Surg* 2005;31:354-8.
11. Machemer R, Aaberg TM, Freeman HM, Irvine AR, Lean JS, Michels RM. An updated classification of retinal detachment with proliferative vitreoretinopathy. *Am J Ophthalmol* 1991;112:159-65.
12. Pastor JC. Proliferative vitreoretinopathy: an overview. *Surv Ophthalmol* 1998;43: 3-18.
13. Charteris DG. Proliferative vitreoretinopathy: pathobiology, surgical management, and adjunctive treatment. *Br J Ophthalmol* 1995;79:953-60.
14. Haynie GD, D'Amico DJ. Scleral buckling surgery. In: Albert DM, Jakobiec FA, eds. *Principles and practice of ophthalmology*. 2nd ed. Philadelphia: W.B. Saunders, 2000:2359-78.
15. Halberstadt M, Chatterjee-Sanz N, Brandenberg L, Koerner-Stiefbold U, Koerner F, Garweg JG. Primary retinal reattachment surgery: anatomical and functional outcome in phakic and pseudophakic eyes. *Eye* 2005;19:891-8.
16. Salicone A, Smiddy WE, Ventkatraman A, Feuer W. Visual recovery after scleral buckling procedure for retinal detachment. *Ophthalmology* 2006;113:1734-42.
17. Diederer RM, La Heij EC, Kessels AGH, Goezinne F, Liem ATA, Hendrikse F. Scleral buckling surgery after macula-off retinal detachment: worse visual outcome after more than 6 days. *Ophthalmology* 2007;114:705-9.
18. Liu F, Meyer CH, Mennel S, Hoerle S, Kroll P. Visual recovery after scleral buckling surgery in macula-off rhegmatogenous retinal detachment. *Ophthalmologica* 2006;220:174-80.
19. Wolfensberger TJ, Gonvers M. Optical coherence tomography in the evaluation of incomplete visual acuity recovery after macula-off retinal detachments. *Graefes Arch Clin Exp Ophthalmol* 2002;240:85-9.
20. Cavallini GM, Masini C, Volante V, Pupino A, Campi L, Pelloni S. Visual recovery after scleral buckling for macula-off detachments: an optical coherence study. *Eur J Ophthalmol* 2007;17:790-6.
21. Theodossiadis PG, Georgalas IG, Emfietzoglou J, et al. Optical coherence tomography findings in the macula after treatment of rhegmatogenous retinal detachments with spared macula preoperatively. *Retina* 2003;23:69-75.
22. D'Amico DJ. Vitreoretinal surgery: principles and applications. In: Albert DM, Jakobiec FA, eds. *Principles and practice of ophthalmology*. 2nd ed. Philadelphia: W.B. Saunders, 2000:2402-21.
23. Thompson JT. The role of patient age and intraocular gas use in cataract progression after vitrectomy for macular holes and epiretinal membranes. *Am J Ophthalmol* 2004;137:250-7.
24. Melberg NS, Thomas MA. Nuclear

- sclerotic cataract after vitrectomy in patients younger than 50 years of age. *Ophthalmology* 1995;102:1466-71.
25. Lincoff H, Weinberger D, Stergiu P. Air travel with intraocular gas. II. Clinical considerations. *Arch Ophthalmol* 1989; 107:907-10.
 26. Wolf GL, Capuano C, Hartung J. Nitrous oxide increases intraocular pressure after intravitreal sulfur hexafluoride injection. *Anesthesiology* 1983;59:547-8.
 27. Campo RV, Sipperley JO, Sneed SR, et al. Pars plana vitrectomy without scleral buckle for pseudophakic retinal detachments. *Ophthalmology* 1999;106:1811-5.
 28. Mendrinos E, Dang-Burgener NP, Stangos AN, Sommerhalder J, Pournaras CJ. Primary vitrectomy without scleral buckling for pseudophakic rhegmatogenous retinal detachment. *Am J Ophthalmol* 2008;145:1063-70.
 29. D'Amico DJ. Diseases of the retina. *N Engl J Med* 1994;331:95-106.
 30. Hilton GF, Grizzard WS. Pneumatic retinopathy: a two-step outpatient operation without conjunctival incision. *Ophthalmology* 1986;93:626-41.
 31. Lincoff H, Mardirossian J, Lincoff A, Liggett P, Iwamoto T, Jakobiec F. Intravitreal longevity of three perfluorocarbon gases. *Arch Ophthalmol* 1980;98:1610-1.
 32. Tornambe PE, Hilton GF. Pneumatic retinopathy: a multicenter randomized controlled clinical trial comparing pneumatic retinopathy with scleral buckling. *Ophthalmology* 1989;96:772-83.
 33. Tornambe PE. Pneumatic retinopathy: the evolution of case selection and surgical technique: a twelve-year study of 302 eyes. *Trans Am Ophthalmol Soc* 1997;95: 551-78.
 34. Eter N, Böker T, Spitznas M. Long-term results of pneumatic retinopathy. *Graefes Arch Clin Exp Ophthalmol* 2000; 238:677-81.
 35. Kulkarni KM, Roth DB, Prenner JL. Current visual and anatomic outcomes of pneumatic retinopathy. *Retina* 2007;27: 1065-70.
 36. Tornambe PE, Hilton GF, Brinton DA, et al. Pneumatic retinopathy: a two-year follow-up study of the multicenter clinical trial comparing pneumatic retinopathy with scleral buckling. *Ophthalmology* 1991;98: 1115-23.
 37. Spitznas M. A binocular indirect ophthalmomicroscope (BIOM) for non-contact wide-angle vitreous surgery. *Graefes Arch Clin Exp Ophthalmol* 1987;225:13-5.
 38. Chang S. Low viscosity liquid fluorochromicals in vitreous surgery. *Am J Ophthalmol* 1987;103:38-43.
 39. Brazitikos PD, D'Amico DJ, Tsinopoulos IT, Stangos NT. Primary vitrectomy with perfluoro-n-octane use in the treatment of pseudophakic retinal detachment with undetected retinal breaks. *Retina* 1999;19:103-9.
 40. Fujii GY, De Juan E Jr, Humayun MS, et al. Initial experience using the transconjunctival sutureless vitrectomy system for vitreoretinal surgery. *Ophthalmology* 2002; 109:1814-20.
 41. Eckardt C. Transconjunctival sutureless 23-gauge vitrectomy. *Retina* 2005;25: 208-11.
 42. Brazitikos PD, Androudi S, Christen WG, Stangos NT. Primary pars plana vitrectomy versus scleral buckle surgery for the treatment of pseudophakic retinal detachment: a randomized clinical trial. *Retina* 2005;25:957-64.
 43. Sharma YR, Karunanithi S, Azad RV, et al. Functional and anatomic outcome of scleral buckling versus primary vitrectomy in pseudophakic retinal detachment. *Acta Ophthalmol Scand* 2005;83:293-7.
 44. Ahmadi H, Moradian S, Faghihi H, et al. Anatomic and visual outcomes of scleral buckling versus primary vitrectomy in pseudophakic and aphakic retinal detachment: six-month follow-up results of a single operation: report no. 1. *Ophthalmology* 2005;112:1421-9.
 45. Wolfensberger TJ. Foveal reattachment after macula-off retinal detachment occurs faster after vitrectomy than after buckle surgery. *Ophthalmology* 2004;111: 1340-3.
 46. Heimann H, Hellmich M, Bornfeld N, Bartz-Schmidt KU, Hilgers RD, Foerster MH. Scleral buckling versus primary vitrectomy in rhegmatogenous retinal detachment (SPR Study): design issues and implications: SPR Study report no. 1. *Graefes Arch Clin Exp Ophthalmol* 2001; 239:567-74.
 47. Heimann H, Bartz-Schmidt KU, Bornfeld N, Weiss C, Hilgers R-D, Foerster MH. Scleral buckling versus primary vitrectomy in rhegmatogenous retinal detachment: a prospective randomized multicenter clinical study. *Ophthalmology* 2007; 114:2142-54.
 48. Ross WH, Lavina A. Pneumatic retinopathy, scleral buckling, and vitrectomy surgery in the management of pseudophakic retinal detachments. *Can J Ophthalmol* 2008;43:65-72.
 49. Schwartz SG, Flynn HW. Primary retinal detachment: scleral buckle or pars plana vitrectomy? *Curr Opin Ophthalmol* 2006;17:245-50.
 50. Saw S-M, Gazzard G, Wagle AM, Lim J, Au Eong K-G. An evidence-based analysis of surgical interventions for uncomplicated rhegmatogenous retinal detachment. *Acta Ophthalmol Scand* 2006;84: 606-12.
 51. Sodhi A, Leung L-S, Do DV, Gower EW, Schein OD, Handa JT. Recent trends in the management of rhegmatogenous retinal detachment. *Surv Ophthalmol* 2008; 53:50-67.
 52. McLeod D. Is it time to call time on the scleral buckle? *Br J Ophthalmol* 2004; 88:1357-9.
 53. Arya AV, Emerson JW, Englebert M, Hagedorn CL, Adelman RA. Surgical management of pseudophakic retinal detachments: a meta-analysis. *Ophthalmology* 2006;113:1724-33.
 54. Weichel ED, Martidis A, Fineman MS, et al. Pars plana vitrectomy versus combined pars plana vitrectomy-scleral buckle for primary repair of pseudophakic retinal detachment. *Ophthalmology* 2006; 113:2033-40.

Copyright © 2008 Massachusetts Medical Society.

COLLECTIONS OF ARTICLES ON THE JOURNAL'S WEB SITE

The Journal's Web site (www.nejm.org) sorts published articles into more than 50 distinct clinical collections, which can be used as convenient entry points to clinical content. In each collection, articles are cited in reverse chronological order, with the most recent first.