

Ultrasound in Emergency Medicine

ULTRASOUND-GUIDED FASCIA ILIACA COMPARTMENT BLOCK FOR HIP FRACTURES IN THE EMERGENCY DEPARTMENT

Lawrence Haines, MD, MPH, RDMS,* Eitan Dickman, MD, RDMS, FACEP,* Sergey Ayvazyan, MD,*
Michelle Pearl, DO, MA, RDMS,* Stanley Wu, MD, MBA, RDMS,† David Rosenblum, MD,‡
and Antonios Likourezos, MA, MPH*

*Department of Emergency Medicine, Maimonides Medical Center, Brooklyn, New York, †Department of Emergency Medicine, Baylor College of Medicine, Houston, Texas, and ‡Department of Anesthesiology, Maimonides Medical Center, Brooklyn, New York
Reprint Address: Lawrence Haines, MD, MPH, RDMS, Division of Emergency Ultrasonography, Department of Emergency Medicine, Maimonides Medical Center, 4802 10th Ave., Brooklyn, NY 11209

Abstract—Background: Hip fracture (HFx) is a painful injury that is commonly seen in the emergency department (ED). Patients who experience pain from HFx are often treated with intravenous opiates, which may cause deleterious side effects, particularly in elderly patients. An alternative to systemic opioid analgesia involves peripheral nerve blockade. This approach may be ideally suited for the ED environment, where one injection could control pain for many hours. **Objectives:** We hypothesized that an ultrasound-guided fascia iliaca compartment block (UFIB) would provide analgesia for patients presenting to the ED with pain from HFx and that this procedure could be performed safely by emergency physicians (EP) after a brief training. **Methods:** In this prospective, observational, feasibility study, a convenience sample of 20 cognitively intact patients with isolated HFx had a UFIB performed. Numerical pain scores, vital signs, and side effects were recorded before and after administration of the UFIB at pre-determined time points for 8 h. **Results:** All patients reported decreased pain after the nerve block, with a 76% reduction in mean pain score at 120 min. There were no procedural complications. **Conclusion:** In this small group of ED patients, UFIB provided excellent analgesia without complications and may be a useful adjunct to systemic pain control for HFx. © 2012 Elsevier Inc.

Keywords—hip fracture; emergency medicine; ultrasound; nerve block; fascia iliaca compartment block; regional anesthesia

INTRODUCTION

Hip fracture (HFx) is a painful orthopedic emergency that commonly presents to the emergency department (ED). In 2007, there were 281,000 hospital admissions in the United States for hip fractures among people age 65 and older (1). It has previously been shown that patients with pain from HFx are under-medicated while in the ED, particularly in overcrowded facilities (2). Current treatment for patients in the ED who are experiencing pain from acute HFx is often with intravenous morphine sulfate (IVMS). IVMS has many undesirable side effects, but of particular concern are delirium, hypotension, and respiratory depression. These effects may be accentuated in elderly patients and necessitate increased patient monitoring and greater utilization of limited ED resources.

An alternative to systemic opioid analgesia involves peripheral nerve blockade. Anesthesiologists frequently perform nerve blocks in the perioperative period to control pain in patients undergoing hip surgery. This approach may be ideally suited for the ED environment, where one injection could control pain for many hours. Evidence suggests that peripheral nerve blockade performed with sonographic guidance decreases the amount of local anesthetic needed to achieve sensory blockade

(3,4). It also increases the success rate of the block and decreases the time to analgesia (5,6).

There are several approaches described to block the nerves that innervate the hip. In a majority of the published studies regarding peripheral nerve blockade for Hfx in the ED, the femoral nerve block or the 3-in-1 femoral nerve block are utilized. Those nerve blocks attempt to place the anesthetic adjacent to the femoral nerve. While targeting the same nerves, the fascia iliaca compartment block (FIB) attempts to place the anesthetic under the plane of the fascia iliaca distant from the nerves of interest. This has been previously described as an effective method for treating pain due to Hfx (7,8). The FIB has been previously shown to provide adequate analgesia for femur fractures in children (9,10). The studies describe the FIB being performed using a technique based on anatomic landmarks and a loss of resistance technique (two tactile “pops” felt as the needle passes through the fascia lata and the fascia iliaca). One recent study in the anesthesia literature has described ultrasound guidance of the FIB (UFIB) increasing the efficacy of the sensory blockade when compared to the loss of resistance technique (11). UFIB has not previously been studied in an adult ED population for Hfx.

We hypothesized that real-time UFIB could be successfully performed in the ED and would provide an excellent adjunct or alternative to repeat doses of IVMS for pain control in patients with Hfx.

MATERIALS AND METHODS

Data were collected prospectively from an academic urban ED with an annual census of over 110,000 patients. This study received approval from our Institutional Review Board. All patients had an initial pain score recorded while being triaged. Patients then underwent an initial evaluation by an emergency physician (EP), and if there was clinical suspicion of Hfx, one of the study investigators was contacted. A standard dose of 0.1 mg/kg of IVMS was given to the patients while they awaited radiographs. The nerve block was not performed until after the patient received the standardized initial dose IVMS and the radiographs were performed.

Patients were eligible for enrollment in the study if the diagnosis of Hfx was confirmed on X-ray study, if they had a pain score of at least 5/10 at triage or upon initial EP evaluation before the IVMS, if there was no pre-hospital analgesia given, and if there were no concomitant injuries. To be included in the study, patients were required to be alert, oriented to person, place, and time, and able to demonstrate understanding of the written informed consent. Patients also had to be able to indicate how much pain they were having on the visual analog pain scale, with 0 being no pain and 10 being severe

pain, and to be able to report any side effects experienced after administration of the nerve blockade.

The pain score assessed just before the nerve block was considered time 0. The patients' vital signs were continuously monitored for a minimum of 1 h after receiving the UFIB. The blocks were performed with dynamic sonographic guidance utilizing a Sonosite Micromaxx or M-turbo (SonoSite, Inc. Bothell, WA) high-frequency 5-10 MHz linear transducer using sterile technique. One of the study investigators (E.D.) trained the other investigators in performing the UFIB, utilizing a short lecture and assisting in their initial attempts until competency was demonstrated. Competency was based on the ability of the trainee to perform the procedure successfully without intervention by the trainer. The number of assisted attempts was not recorded.

To perform this block, the two fascial planes, the fascia lata and the fascia iliaca, were sonographically visualized as two hyperechoic lines, with the probe placed in a transverse orientation on the thigh just inferior to the inguinal ligament and one-third of the distance from the anterior superior iliac spine to the pubic tubercle (Figure 1A, B). A 22-gauge spinal needle was introduced through the skin in a lateral-to-medial orientation and was directed in parallel with the transducer to allow visualization of the full length of the needle throughout the procedure. The needle tip was visualized penetrating the fascia lata and then the fascia iliaca (Figure 1C). After puncturing the fascia iliaca, 30 mL of 0.25% bupivacaine was injected. An expanding anechoic collection just below the fascia iliaca was visual confirmation of correct placement of anesthetic (Figure 1D).

Patients were eligible to receive standardized rescue doses of IVMS after UFIB placement if they experienced continued pain. A 0.1-mg/kg rescue dose was given if requested. This was followed by 0.05-mg/kg doses if requested. Vital signs, pain scores, amount of morphine, and side effects were monitored at predetermined time points for 8 h.

RESULTS

A convenience sample of 20 patients was enrolled in this study. Nerve blocks were placed by two emergency ultrasound fellowship-trained EPs, one emergency ultrasound fellow, or three 3rd-year emergency medicine residents (always with one of the EPs present). Eleven patients were female. The mean age of the patients was 82 years (SD \pm 7.7 years); 55% of the Hfx were intertrochanteric. The remaining 45% of the fractures involved the femoral neck. Data were not obtained in 3 patients at the 480-min time point.

The mean pain score at triage was 7.9/10. Shortly after triage, patients received the first dose of 0.1 mg/kg of

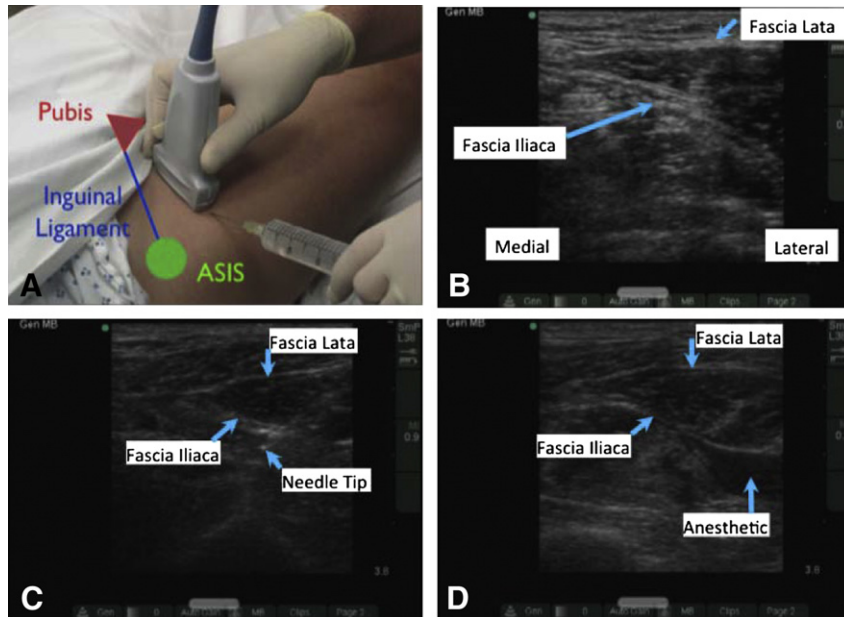


Figure 1. (A) Placing the ultrasound-guided fascia iliaca compartment block (UFIB). ASIS = anterior superior iliac spine. (B) Ultrasound visualization of the fascia lata and fascia iliaca. Note the medial and lateral orientation. (C) Ultrasound image just before injection. Note the needle tip deep to the fascia iliaca. (D) Image after injection of local anesthetic. Note the anechoic collection of local anesthetic just beneath the plane of the fascia iliaca.

IVMS while awaiting radiographs. Time until radiographs were performed was, on average, 119 min (SD \pm 51 min). Time 0 was recorded just before the administration of the nerve block, and the mean pain score at time 0 was 5.5/10. Over the next 8 h, the patients reported a statistically significant lower mean pain score as compared to time 0 (Figure 2). The lowest mean pain score of 1.3/10 was achieved at time 120 min, which represents a 76% drop in pain from just before the placement of the block. All of the decrease in pain scores were statistically significant, with *P*-values for the time points of 0.029 (time 0 vs. time 10 min); 0.0001 (time 0 vs. time 20 min); 0.0001 (time 0 vs. time 30 min); 0.001 (time 0 vs. time 60 min); 0.0001 (time 0 vs. time 120 min); 0.0001 (time 0 vs. time 240 min); and 0.017 (time 0 vs. time 480 min), respectively.

After receiving the nerve block, 80% of the patients did not request additional analgesia. Of the 4 patients that requested the standardized doses of additional analgesia, 2 patients received one dose of additional analgesia at 120 min, and 2 patients received one dose at 240 min.

There were no procedural complications from the nerve block. Eighty-five percent of the patients reported no side effects within the 8 h of data collection. Of the 3 patients that reported side effects, one patient reported nausea and vomiting at 30 min. The second patient reported dizziness, sleepiness, nausea, and vomiting at 10 min and then only sleepiness at 20 min, with no additional reported side effects at the later time points. The

third patient reported dizziness at every time point, as well as blurred vision at 240 min and then nausea at 480 min. Only this patient out of the 3 that reported side effects requested an additional dose of analgesia, which was given at 120 min.

DISCUSSION

The UFIB was chosen because it targets the femoral, obturator, and lateral femoral cutaneous nerves that innervate the hip joint and the area around the hip, and it has

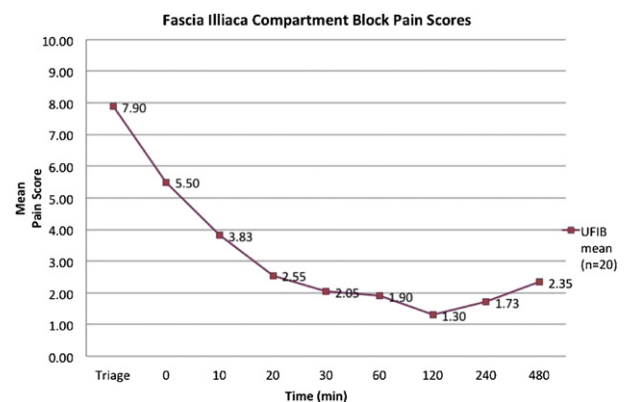


Figure 2. Mean pain scores. “Triage” is the pain score at triage and just before receiving intravenous morphine. Time 0 pain score is just before the nerve block, but after the morphine. UFIB = ultrasound-guided fascia iliaca compartment block.

been shown to provide effective analgesia for HFx. An additional advantage of this particular nerve block is that the needle is relatively far from the critical vascular structures of the proximal thigh, including the femoral vein and femoral artery. Sonographic identification of nerves, which can be challenging in some patients, is not necessary for this block. It has been our experience that the traditional landmark-based technique, described as two tactile “pops” felt as the needle passes through the fascia lata and then the fascia iliaca, is often not obvious or discernable, especially in the frail, elderly patient. Ultrasound guidance helped to ensure that we avoided vascular structures and allowed us to visualize the correct placement of local anesthetic.

Our medical center’s institutional review board required that HFx be confirmed radiographically before placement of the nerve blockade. Due to the resource constraints of the imaging department in our high-volume, high-acuity, urban ED, it is not unusual for patients to wait 2 h for radiographs. It was deemed unethical to withhold analgesia during this interval, so we elected to give all of our patients a weight-based dose of morphine after initial evaluation.

The drop in pain score from triage to time 0 was likely due to the morphine. In this case series, X-ray studies were completed an average of 119 min (SD \pm 51 min) after the patient was triaged. This was followed by administration of the nerve block. Therefore, we believe that from time 0 until the 8-h time point, the decrease in pain was likely due to the analgesia provided by the nerve blockade, as this was outside the time to the maximal effect of morphine.

Anesthesiologists routinely place nerve blocks for pain control in the operating room and postoperative period, but have traditionally used nerve stimulators to guide their placement. Most EPs do not routinely use nerve stimulators. However, EPs are increasingly facile with ultrasonography, and there is good evidence to show that peripheral nerve blocks performed with ultrasound guidance can be placed with less anesthetic and greater success. Sonographic guidance may increase the confidence of EPs in placing these blocks and may make placing a UFIB more routine in the ED.

We chose bupivacaine as the local anesthetic due to its proven safety, widespread availability, and long-lasting effects.

Limitations

The major limitations of this study include its small sample size and lack of control group. For the purpose of demonstrating feasibility, it seems that the UFIB can be successfully placed by EPs after a brief training period and that it does decrease pain scores. A follow-up prospec-

tive, randomized, controlled study with a larger sample size would be needed to confirm these preliminary data.

The emergency physicians performing the UFIB were emergency ultrasound-trained attendings, emergency ultrasound fellows, or 3rd-year emergency medicine residents who showed an interest in pursuing a fellowship in emergency ultrasonography. Although this represented a spread in the training levels of the practitioners performing the block, all of the physicians involved showed a greater-than-average level of interest and proficiency in emergency ultrasound. Further studies are necessary to determine whether these results can be generalized to all EPs, including those without ultrasound training.

The patients enrolled in this study were a convenience sample of patients that presented to the ED when the study investigators were available to enroll the patients, to perform the block, and to observe the patient for 8 h after the block. This may have introduced selection bias. Also, patients that did consent to enrollment may have been in a greater amount of pain than those that chose not to participate.

Another limitation was giving morphine to all patients as they waited for X-ray studies. Although the nerve block was placed, on average, 2 h after the initial dose of morphine, the systemic analgesia may have exaggerated the perceived effect of the local nerve blockade. In addition, the 4 patients who received rescue analgesia were included in the analysis of the pain scores. One would expect that this would increase the perceived efficacy of the UFIB.

Morphine was not only a potential confounder with the pain scores, but may have caused the side effects that were reported. Three patients reported nausea, vomiting, dizziness, sleepiness, and blurred vision, and we did not ask patients about side effects until after the block was placed. We do not know if these side effects were present before the UFIB, so we cannot say if they were caused by the opiates or by the block itself.

Lastly, pain scores were sometimes collected by the same person who performed the block, and this is a potential source of bias. We tried to use separate personnel as data collectors, but due to resource limitations, it was often the person who placed the UFIB who was performing the data collection as well. In some patients, data collection was a combined effort among several people on the research team. We did not keep records of who was performing the data collection.

CONCLUSION

The results of this study suggest that the ultrasound-guided fascia iliaca compartment block can be placed safely by EPs who have received brief training in this technique for pain control in patients with acute hip fracture.

The nerve block provided excellent analgesic benefit for patients and is a viable adjunct to systemic pain control.

Acknowledgment—This study received funding from the Emergency Medicine Basic Research Skills grant by the Emergency Medicine Foundation in 2009.

REFERENCES

1. Department of Health and Human Services, the Centers for Disease Control. National Hospital Discharge Survey (NHDS), National Center for Health Statistics, 2004. Available at: <http://www.cdc.gov>.
2. Hwang U, Richardson LD, Sonuyi TO, Morrison RS. The effect of emergency department crowding on the management of pain in older adults with hip fracture. *J Am Geriatr Soc* 2006;54:270–5.
3. Marhofer P, Schrögendorfer K, Wallner T, et al. Ultrasonographic guidance reduces the amount of local anesthetic for 3-in-1 blocks. *Reg Anesth Pain Med* 1998;23:584–8.
4. Casati A, Baciarello M, Di Cianni S, et al. Effects of ultrasound guidance on the minimum effective anaesthetic volume required to block the femoral nerve. *Br J Anaesth* 2007;98:823–7.
5. Marhofer P, Schrögendorfer K, Koinig H, et al. Ultrasonographic guidance improves sensory block and onset time of three-in-one blocks. *Anesth Analg* 1997;85:854–7.
6. Reid N, Stella J, Ryan M, et al. Use of ultrasound to facilitate accurate femoral nerve block in the emergency department. *Emerg Med Australas* 2009;21:124–30.
7. Foss NB, Kristensen BB, Bundgaard M, et al. Fascia iliaca compartment blockade for acute pain control in hip fracture patients: a randomized, placebo-controlled trial. *Anesthesiology* 2007;106:773–8.
8. Monzon DG, Iserson KV, Vazquez JA. Single fascia iliaca compartment block for post-hip fracture pain relief. *J Emerg Med* 2007;32:257–62.
9. Wathen JE, Gao D, Merritt G, et al. A randomized controlled trial comparing a fascia iliaca compartment nerve block to a traditional systemic analgesic for femur fractures in a pediatric emergency department. *Ann Emerg Med* 2007;50:162–71.
10. Dalens B, Vanneuville G, Tanguy A. Comparison of the fascia iliaca compartment block with the 3-in-1 block in children. *Anesth Analg* 1989;69:705–13.
11. Dolan J, Williams A, Murney E, et al. Ultrasound guided fascia iliaca block: a comparison with the loss of resistance technique. *Reg Anesth Pain Med* 2008;33:526–31.

ARTICLE SUMMARY

1. Why is this topic important?

Hip fracture is a painful condition and most often occurs in elderly patients, who may be sensitive to the side effects of morphine. Ultrasound usage and skill among emergency physicians is increasing. Using ultrasound to guide peripheral nerve blockade may make placing a nerve block in the emergency department (ED) more routine as an adjunct to systemic opiates, as it has the potential to make the procedure safer and more efficacious.

2. What does this study attempt to show?

This study is the first time an ultrasound-guided fascia iliaca block is described in the adult Emergency Medicine setting. This study attempts to show that the block can be placed safely by emergency physicians, and that it provides analgesic benefit to patients with acute hip fracture. We feel that this nerve block is easier to place than the femoral nerve block because there is no need to identify the femoral nerve, and the technical challenge of placing the local anesthetic adjacent to the nerve is absent.

3. What are the key findings?

This nerve block was associated with no procedural side effects and reduced pain to a maximum of 76% at 120 min after the placement of the nerve block.

4. How is patient care impacted?

This may make placing a nerve block under ultrasound guidance more routine and may make peripheral nerve blockade a viable adjunct to systemic pain control for hip fracture in the ED.