

Intraarticular Injection and Closed Glenohumeral Reduction with Emergency
Ultrasound

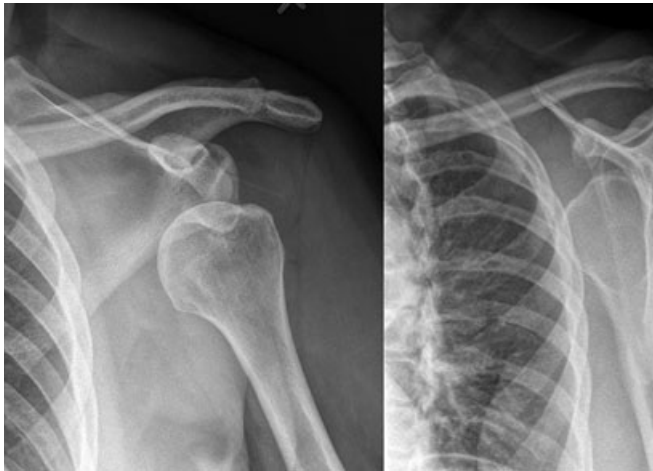

Figure 1. Anteroposterior and scapular Y radiographs demonstrate subcoracoid glenohumeral dislocation.

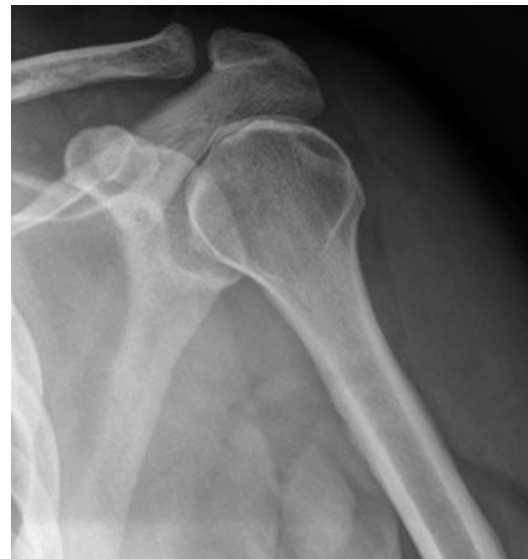

Figure 3. Postreduction anteroposterior radiograph confirms successful reduction of glenohumeral dislocation.

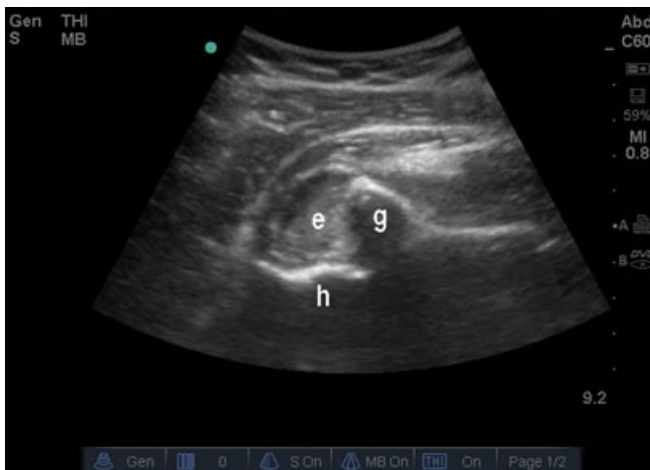


Figure 2. Ultrasound image obtained from posterior aspect of shoulder demonstrates glenoid (g), joint effusion (e) with hyper-echoic hemarthrosis, and anteriorly displaced proximal humerus (h).

A 52-year-old man with no significant medical history presented to the emergency department (ED) after a mechanical fall onto his nondominant left hand. Physical

examination was suggestive of a glenohumeral dislocation, and radiographs confirmed a subcoracoid anterior glenohumeral dislocation (Figure 1). The patient was neurovascularly intact, but complained of severe pain and refused initial attempts to manipulate his arm.

A bedside ultrasound was performed via a posterior approach using a low-frequency curvilinear transducer and demonstrated an empty glenoid fossa with hemarthrosis and anterior displacement of the proximal humerus (Figure 2). After informed consent was obtained and sterile preparation, a real-time ultrasound-guided intra-articular glenohumeral joint injection was performed using a 22-gauge spinal needle and 20 mL of 1% lidocaine with epinephrine. The needle was visualized as it approached and entered the glenohumeral joint (Video Clip S1, available as supporting information in the online version of this paper [e = effusion, g = glenoid, h = humerus, n = needle]), and local anesthetic was seen filling the glenoid fossa during injection (Video Clip S2 [e = effusion, g = glenoid, h = humerus, n = needle]). The patient underwent an uncomplicated closed reduction using the Spaso technique, and postprocedural ultrasound (Video Clip S3 [hh = humeral head, g = glenoid])

and subsequent radiography (Figure 3) confirmed successful reduction.

Michael B. Stone, MD, RDMS

(drmikestone@gmail.com)

Darrell Sutijono, MD

*Department of Emergency Medicine,
SUNY Downstate/Kings County Hospital Center,
Brooklyn NY*

Supporting Information

The following supporting information is available in the online version of this paper:

Video Clip S1. Needle visualized as it approached and entered the glenohumeral joint.

The video clip is in QuickTime.

Video Clip S2. Local anesthetic seen filling the glenoid fossa during injection.

The video clip is in QuickTime.

Video Clip S3. Postprocedure ultrasound.

The video clip is in QuickTime.