

Mitral-Septal Separation: New Echocardiographic Index of Left Ventricular Function

BARRY M. MASSIE, MD
NELSON B. SCHILLER, MD, FACC
ROBERT A. RATSHIN, MD, FACC
WILLIAM W. PARMLEY, MD, FACC

San Francisco, California

An echocardiographic measurement of the minimal separation between the anterior mitral valve leaflet at its E point and the interventricular septum was evaluated as an index of left ventricular function. Mitral-septal separation was found to be easily measured, reproducible and independent of patient position or heart rate changes of up to 32 beats/min. In a group of 30 normal subjects, E point-septal separation was absent in 25 and minimal (less than 4 mm) in the remaining 5. The relation of this variable to biplane angiographic ejection fraction was examined in 125 patients with a variety of cardiac diseases. After the 15 patients with mitral stenosis and aortic insufficiency (conditions that affect anterior leaflet motion) were excluded, a strong negative correlation ($r = -0.87$, $P < 0.001$) was found between mitral-septal separation and ejection fraction in the remaining 110. The correlation remained high ($r = -0.86$, $P < 0.001$) when the 60 patients with coronary artery disease were considered separately. When compared with other echographic indexes of ventricular function, E point-septal separation correlated more closely with angiographic ejection fraction and was more useful in discriminating between patients with normal and those with low ejection fraction. This index appears to be especially useful because of the simplicity of its determination and its reliability in patients with coronary artery disease. We hypothesize that mitral-septal separation is determined by multiple hemodynamic and geometric factors but in most patients reflects an interplay between the amount and rate of early diastolic ventricular filling and ventricular size.

Measurements of left ventricular performance have proved to be important indicators of prognosis in patients with many forms of heart disease.¹ In patients undergoing valve replacement or coronary arterial revascularization, preoperative ejection fraction in particular has been a good predictor of the risks and results of surgery.² Consequently, there has been a great deal of interest in the noninvasive evaluation of left ventricular function with echocardiography.³ Several groups have found correlations between echocardiographically and angiographically determined ejection fraction⁴⁻⁸ and other measures of contractile function.⁹ However, others have found echographic indexes of ventricular function to be unreliable in patients with segmental asynergy resulting from coronary artery disease.¹⁰⁻¹³

We have observed that in normal subjects the anterior mitral valve leaflet makes contact with or closely approaches the interventricular septum in early diastole, at the E point in its cycle. In patients with depressed ventricular function we have noted increased mitral E point-septal separation. Similarly, in patients with papillary muscle dysfunction or congestive cardiomyopathy a pattern of posterior displacement of the mitral valve apparatus has been described,^{14,15} whereas in patients with increased contractile function, the mitral valve has been noted to appose the septum in early diastole.¹⁶

From the Department of Medicine, Cardiovascular Division, and the Cardiovascular Research Institute, University of California, San Francisco, California. This work was supported in part by Program Project Grant HL 06285 from The National Heart, Lung, and Blood Institute, National Institutes of Health, Bethesda, Maryland. Manuscript received August 30, 1976; revised manuscript received November 16, 1976, accepted December 14, 1976.

Address for reprints: Barry M. Massie, MD, Room 1186, Moffitt Hospital, University of California, San Francisco, California 94143.

This study was undertaken to determine (1) whether measurements of mitral-septal separation provide a useful measure of ventricular function in a large and diverse group of patients undergoing cardiac catheterization, and (2) whether they remain reliable in patients with coronary artery disease.

Methods

Patient population: A total of 160 patients underwent echocardiographic examination and biplane left ventriculography within an interval of 5 days (within 48 hours in 146 patients) over a 15 month period at our institution. No patient who manifested a significant change in clinical status between the two studies was included. Thirty-five patients were excluded because angiographic (15 cases) or echocardiographic (20 cases) studies were technically inadequate for analysis. The remaining 125 patients form the basis for this report. The primary cardiac diagnoses, established with hemodynamic measurements, oximetry, ventriculography and selective coronary arteriography, are listed in Table I. In addition, 30 normal subjects without clinical, historical or electrocardiographic evidence of heart disease were studied echocardiographically.

Echocardiographic measurements: Echocardiograms were performed using commercially available 0.5 inch (1.27 cm), 2.25 megahertz transducers with repetition rates of 1,000 cycles/sec, nominally focused at 7.5 or 10 cm, and Picker Echoview 10 ultrasonoscopes. The time-motion output was recorded on either a Honeywell model 1856 or an Irex strip chart recorder. The patients were positioned in semirecumbent posture (with 15 to 30° of truncal elevation) in various degrees of left lateral decubitus rotation. The interspace from which one or both mitral valve leaflets could be well visualized while the transducer was held perpendicularly to the chest wall (usually the fourth) was determined, and a sweep from that area was recorded between the aortic valve and apex of the left ventricle.

The left ventricular dimensions were determined at a level just below the anterior mitral valve leaflet, where chordal echoes were still visible. The end-diastolic dimension (EDD) was measured at the peak of the simultaneously recorded electrocardiographic R wave, and the end-systolic dimension (ESD) was defined as the closest approximation of the interventricular septum to the posterior wall endocardium during the same cardiac cycle.

The percent shortening of the echographic minor axis (%S) was calculated using the formula:

TABLE I

Patient Diagnoses

Coronary artery disease	60	
Valvular heart disease	39	
Aortic stenosis		12
Aortic insufficiency		7
Mitral stenosis		6
Mitral insufficiency		7
Mixed valvular disease		7
Cardiomyopathy	11	
Congestive		6
Hypertrophic		4
Restrictive		1
Congenital heart disease	9	
Atrial septal defect		4
Ventricular septal defect		3
Other		2
No heart disease	6	

$$\%S = \frac{EDD - ESD}{EDD}$$

An echocardiographic ejection fraction was computed using the formulae for end-systolic volume (ESV) and end-diastolic volume (EDV) developed by Teichholz et al.¹²:

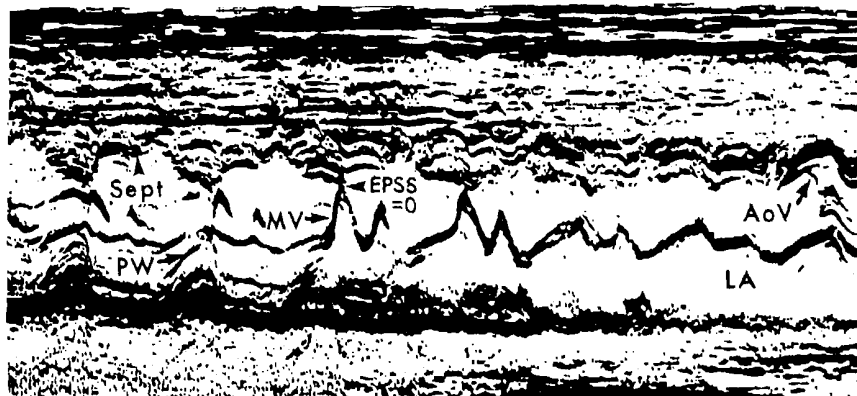
$$ESV = \frac{7.0}{2.4 + ESD} (ESD)^3$$

$$EDV = \frac{7.0}{2.4 + EDD} (EDD)^3$$

$$EF = \frac{EDV - ESV}{EDV}$$

Determination of mitral-septal separation: The amount of mitral-septal separation was defined as the perpendicular distance between the E point of the anterior mitral leaflet and a tangent drawn to the most posterior point reached by the interventricular septum within the same cycle. This method of measuring mitral-septal separation allowed the inclusion of five patients with paradoxical septal motion (four with an atrial septal defect, one with septal infarction) and others with flat or reduced septal motion. Mitral-septal separation was measured in the view in which it was minimized, usually at or just below the junction of the left atrial and left ventricular posterior walls, at a level in which both mitral leaflets were well seen (Fig. 1). A normalized index of E point separation was computed by dividing the measured amount of mitral-septal separation by the echographic end-diastolic dimension.

FIGURE 1. M mode echographic sweep from the left ventricular apex to the aortic valve in a normal subject, demonstrating the normal close approximation between the anterior mitral valve (MV) leaflet at its E point and the interventricular septum (Sept). The arrowhead indicates the level at which E point-septal separation (EPSS) is measured, at or just below the left atrial-left ventricular junction where both mitral valve leaflets are well visualized. In this case no separation is present. AoV = aortic valve; LA = left atrium; PW = posterior wall.



There was no change in mitral-septal separation in several subjects who were examined in different degrees of left lateral decubitus positioning. In 25 patients, two independent observers obtained echocardiograms and measured the amount of mitral-septal separation. The differences between the two determinations were small, ranging from 0 to 2 mm in patients with little E point separation (less than 10 mm) and 0 to 4 mm in those with greater separation (10 to 28 mm). The mean of the absolute differences between the two sets of measurements was 1 mm, which was proportionally 10 percent of the mean amount (10 mm) of mitral-septal separation in these 25 patients.

Cardiac catheterization and angiographic measurements: These were performed in the postabsorptive state after premedication with diazepam (Valium®), 10 mg given intramuscularly. Biplane left ventricular cineangiograms were taken in 30° right anterior oblique and 60° left anterior oblique projections after an injection of 45 cc of a 66 percent meglumine diatrizoate, 10 percent sodium diatrizoate solution (Renografin 76®) over 3 seconds. Left ventricular volumes at end-diastole and end-systole were obtained by the modified Simpson's rule method of Goerke and Carlsson.¹⁷ The ventricular ejection fraction was calculated as the ratio of angiographic stroke volume to end-diastolic volume. An ejection fraction of 55 percent was arbitrarily taken as the lower limit of the normal range. Segmental wall motion was assessed qualitatively by an experienced angiographer. Stroke volume was determined both angiographically and by the Fick method.

Results

Mitral-septal separation in normal subjects:

Twenty-five of the 30 normal subjects, including the one

whose echocardiogram is shown in Figure 1, had no mitral-septal separation, and each of the remaining 5 had less than 4 mm separation. E point separation was also less than 4 mm in the six patients who had no evidence of cardiac disease at the time of catheterization and angiography.

Relation of mitral-septal separation to heart rate and rhythm: Echocardiograms from 10 patients who manifested spontaneous changes in sinus rate of 14 to 32 beats/min (mean 22 beats) during the examination were analyzed to determine whether there was any rate-dependent variation in E point separation. No difference in the magnitude of mitral-septal separation was present from cycle to cycle in these patients. Only two patients in the final study group did not have sinus rhythm, and both had atrial fibrillation with relatively regular ventricular responses (less than 25 percent variation in cycle length). In these two patients, the magnitude of mitral-septal separation remained almost constant (with a maximum of 2 mm), as did the ejection fraction, which was determined for several different cycles of the ventriculogram.

Relation of mitral-septal separation to ventriculographic ejection fraction: Fifteen of the 125 patients had mitral stenosis or at least moderate aortic regurgitation, conditions in which normal mitral anterior leaflet motion is restricted. In these patients, no consistent relation between the degree of E point separation and other echographic or angiographic indexes of ventricular function was present. However, among

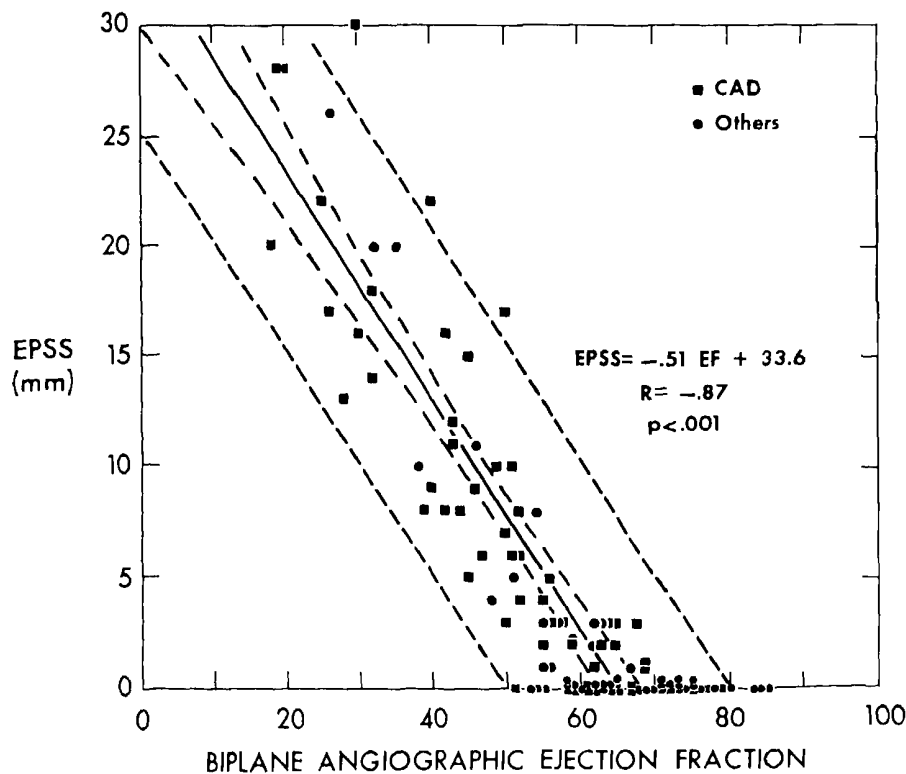


FIGURE 2. Correlation between E point-septal separation (EPSS) and biplane angiographic ejection fraction (EF). Inner and outer pairs of interrupted lines are 95 percent confidence limits for the regression line and for the points, respectively. Patients with coronary artery disease (CAD) are indicated by squares. p = probability; R = correlation coefficient.

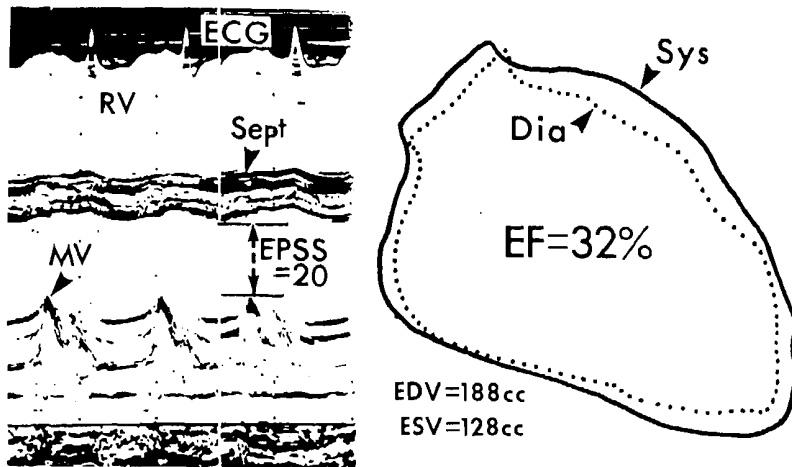


FIGURE 3. Echocardiogram and right anterior oblique ventriculographic outlines from a patient with alcoholic cardiomyopathy, demonstrating considerable E point-septal separation (EPSS) and a low ejection fraction (EF). Dia = diastole; ECG = electrocardiogram; EDV and ESV = end-diastolic and end-systolic volumes, respectively; MV = mitral valve; RV = right ventricle; Sept = interventricular septum; Sys = systole.

the patients with aortic insufficiency, mitral-septal separation was always larger (greater than 8 mm) in those with more severe regurgitation or with concomitantly reduced ejection fraction.¹⁸

The relation between mitral-septal separation and biplane angiographic ejection fraction in the remaining 110 patients is shown in Figure 2. In this, and in succeeding graphs, data from the patients without mitral-septal separation were plotted but were excluded from the linear regression analysis because the measured separation cannot be less than zero. There was a highly significant negative correlation between the magnitude of E point separation and ejection fraction ($r = -0.87$, $P < 0.001$) which held over a wide range. Figure 3, taken from the echocardiogram of a patient with severe alcoholic cardiomyopathy and a considerably depressed ejection fraction, demonstrates the large amount of mitral-septal separation in patients with poor ventricular function in contrast to that in normal subjects (Fig. 1).

Relation of mitral-septal separation to left ventricular size and stroke volume: The possibility that the magnitude of mitral-septal separation was determined primarily by stroke volume or ventricular size rather than by ventricular function was evaluated. Among the 90 patients with less than 10 percent difference in heart rate between the echographic and angiographic studies, no relation was detected between the E point separation and stroke volume, as determined either angiographically or with the Fick method ($r = 0.24$, $P > 0.05$ and $r = 0.22$, $P > 0.05$, respectively).

Because many patients with ventricular enlargement also manifested reduced ventricular function, some degree of correlation between mitral-septal separation and ventricular size was expected even if ventricular dimensions were not a major determinant of this variable. However, the correlations between E point separation and both angiographic end-diastolic volume ($r = 0.51$) and echographic end-diastolic dimension ($r = 0.62$) were surprisingly poor. When the respective cor-

relations at E point separation with end-diastolic dimension and angiographic ejection fraction are compared in these 110 patients, mitral-septal separation correlates more closely with ejection fraction than with echographic end-diastolic dimension ($P < 0.01$) (Fig. 4). Indeed, there were five patients (one with acute mitral regurgitation, two with chronic mitral regurgitation and two with ventricular septal defect) with a volume-overloaded normally functioning left ventricle. Each of

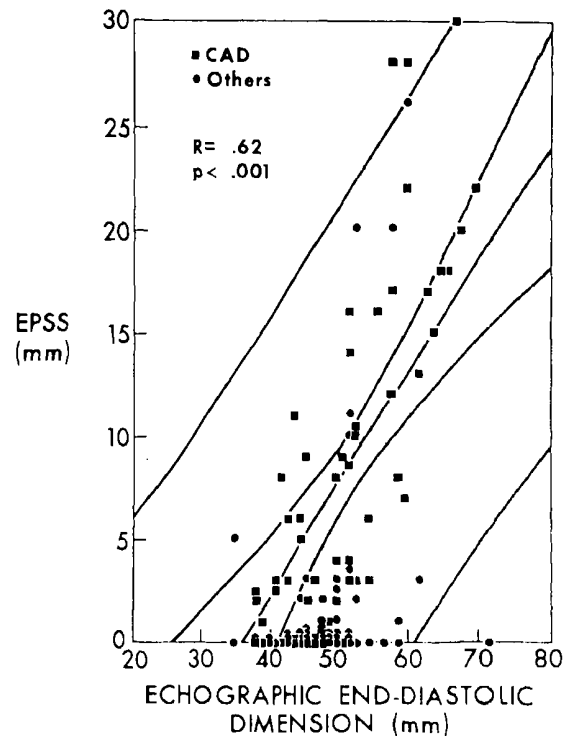


FIGURE 4. Relation between E point-septal separation (EPSS) and echographic end-diastolic dimension. Abbreviations as in Figure 2.

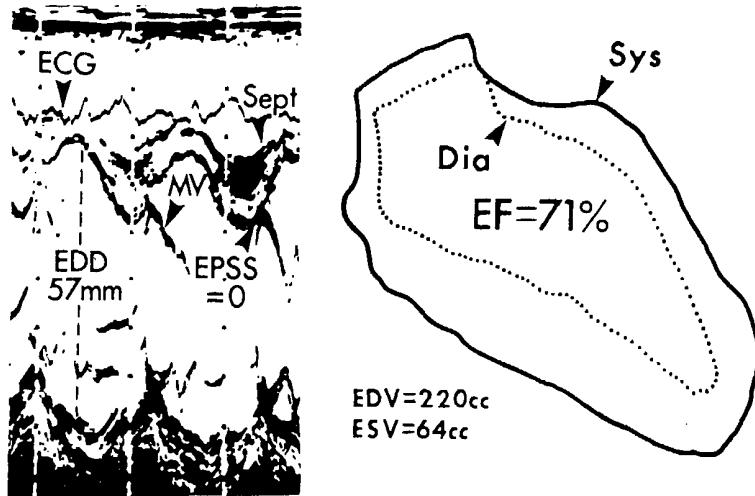


FIGURE 5. Echocardiogram and ventriculogram from a patient with ruptured chordae tendineae and acute volume overload. Despite increased end-diastolic dimension (EDD) at this level (and at the chordal level not illustrated here) and chamber dilatation, there is no E point-septal separation (EPSS), consistent with normal ejection fraction (EF). Abbreviations as in Figure 3.

the five had an increased echographic diastolic dimension and only a small amount of E point separation. Conversely, there were 15 patients with normal end-diastolic dimension and reduced angiographic ejection fraction, and 12 of these had increased E point separation (more than 5 mm). In 11 of these, the other echocardiographic indexes of ventricular function were normal.

Figure 5 reproduces the echocardiogram and ventriculographic outlines from a patient with acute mitral regurgitation and volume overload. Despite ventricular dilatation (echographic end-diastolic dimension = 57 mm; angiographic end-diastolic volume = 220 cc), there is no mitral-septal separation, thus indicating preserved ventricular function. The studies illustrated in Figure 6 are taken from a patient who presented in severe bi-ventricular failure with a normal cardiac silhouette on chest X-ray examination. The finding of 10 mm of mi-

tral-septal separation in the face of a small left ventricle (end-diastolic dimension = 45 mm; angiographic end-diastolic volume = 88 cc) suggested the presence of depressed contractile function, which was eventually confirmed during cardiac catheterization.

Figure 7 demonstrates the relation between mitral-septal separation normalized for echographic end-diastolic dimension and angiographic ejection fraction. Again, a highly significant negative correlation is present ($r = -0.86, P < 0.001$), indicating that this index is a useful indicator of ventricular function independent of chamber size. A ratio of 0.1 provides an excellent demarcation between patients with normal (55 percent and greater) and reduced ejection fraction. Only one patient with a normal ejection fraction and four with a low ejection fraction had normalized E point separation inappropriately above or below 0.1. Because the relation between the normalized index and ejection fraction is

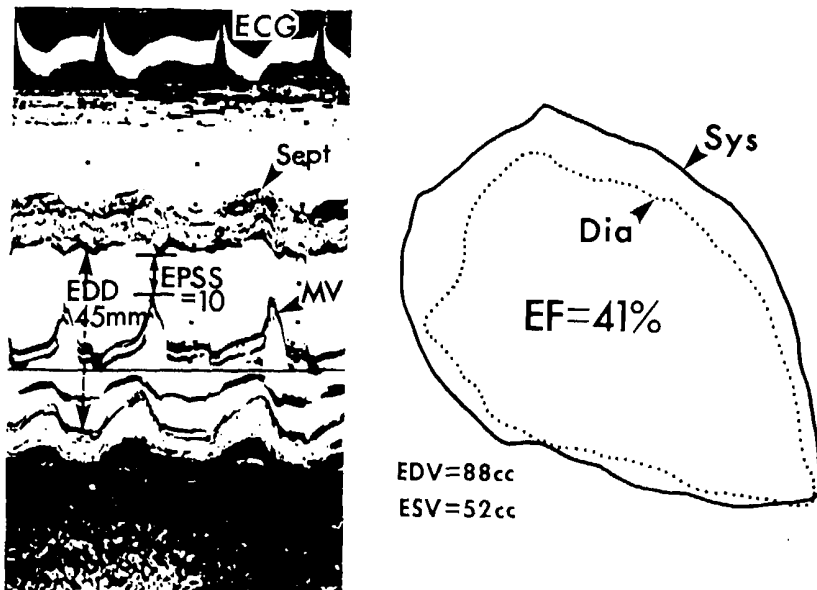


FIGURE 6. Echocardiogram and ventriculographic outlines from a patient with restrictive cardiomyopathy. Echographic dimensions at the mitral valve (MV) and chordal levels and angiographic volumes are small, but E point-septal separation (EPSS) is increased and ejection fraction (EF) reduced. Abbreviations as in Figure 3.

similar to that between E point separation itself and ejection fraction, normalization is not routinely performed in our laboratory. The normal range for un-normalized mitral-septal separation is defined as less than 5 mm, a value that corresponds to a normalized

index of less than 0.1 in patients with normal ventricular dimensions.

Mitral-septal separation in patients with coronary artery disease: The utility of this index was examined more closely in the patients with coronary artery

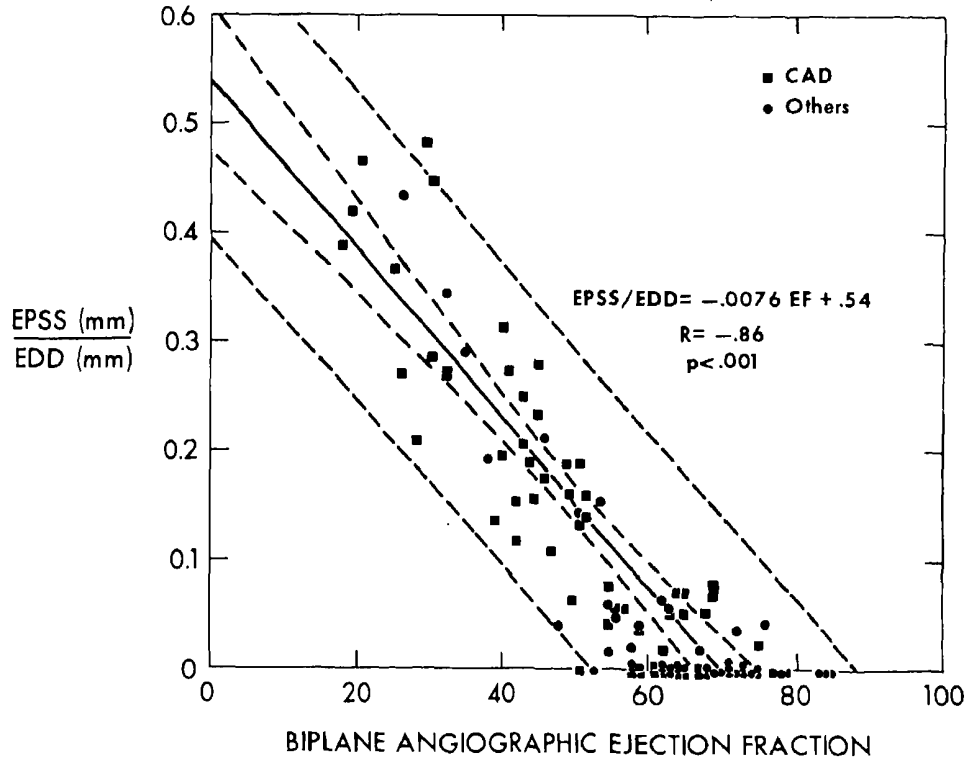


FIGURE 7. Relation between E point-septal separation (EPSS), normalized for echographic end-diastolic dimension (EDD), and angiographic ejection fraction (EF). Abbreviations as in Figure 2.

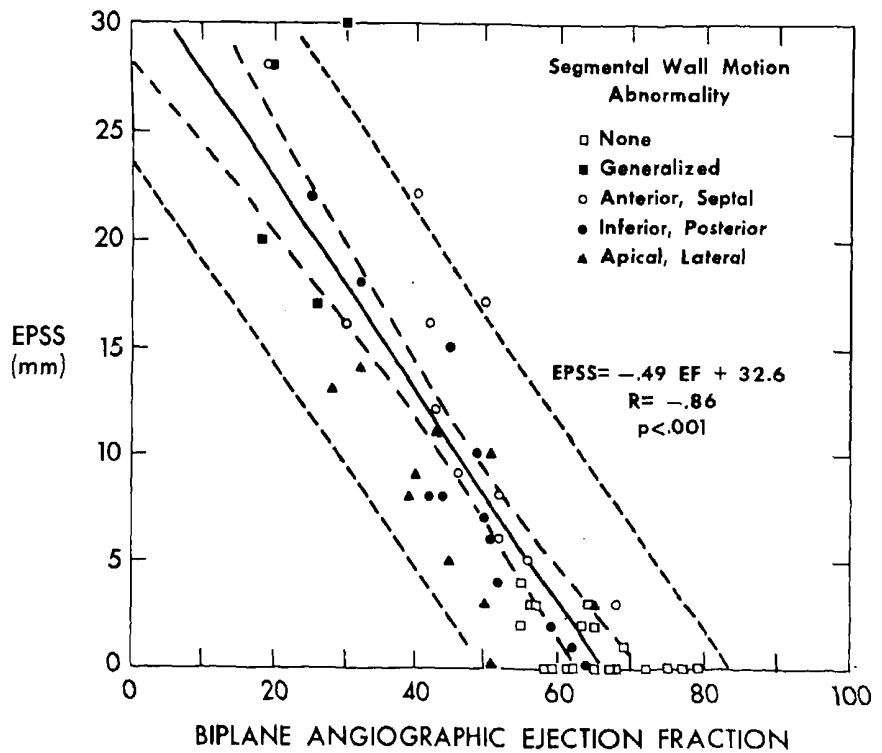


FIGURE 8. Relation between E point-septal separation (EPSS) and angiographic ejection fraction (EF) in patients with coronary artery disease. Symbols indicate areas of major segmental asynergy. Abbreviations as in Figure 2.

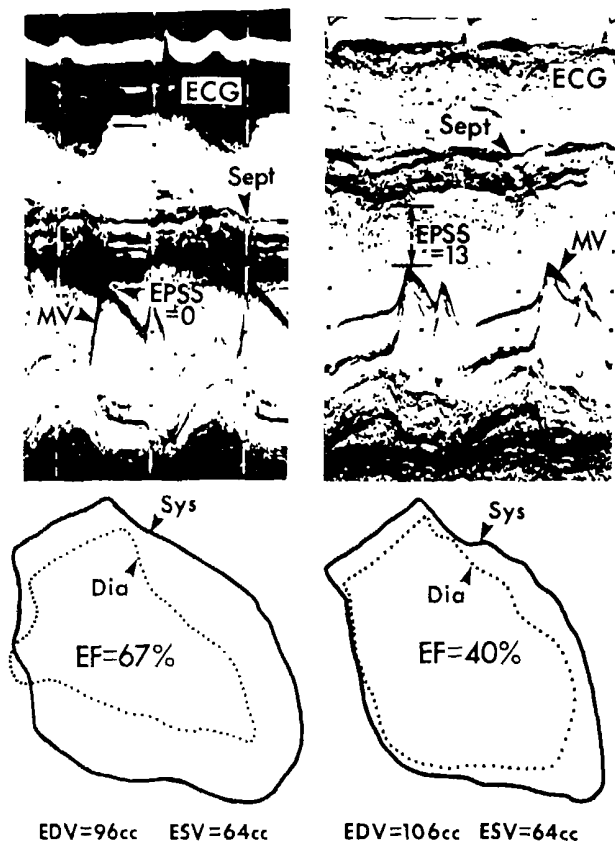


FIGURE 9. Echocardiograms and ventriculograms performed 1 year apart in a patient who had an inferior wall myocardial infarction 6 weeks before the second study (right), demonstrating interval appearance of abnormal E point-septal separation (EPSS) and decreased in ejection fraction (EF). Abbreviations as in previous figures.

disease because other echocardiographic measures of ventricular function are less reliable in this setting. Figure 8 is a graph of mitral-septal separation versus ejection fraction in the patients with coronary disease. The correlation ($r = -0.86, P < 0.001$) is similar to that recorded for the entire patient group, and indeed the regression equations are nearly identical for both groups. When the region of abnormal wall motion is considered, there was some tendency for E point separation to be less than expected for the observed reduction in ejection fraction in patients with predominant apical-lateral asynergy. It was also greater than expected in two patients with antero-septal asynergy (one with paradoxical and another with flat septal motion). Nonetheless, mitral-septal separation remained a good predictor of reduced ventricular function and continued to correlate closely with ejection fraction in most of the patients with these segmental disorders. Figure 9 illustrates serial echocardiograms and ventriculograms from a patient who had normal ventricular function and no E point separation when first seen and who then, after an inferior wall myocardial infarction, had a considerably lower ejection fraction and 13 mm of separation.

Comparison of mitral-septal separation with other echocardiographic indexes of ventricular

TABLE II

Superiority of E Point-Septal Separation (EPSS) Over Other Echocardiographic Indexes of Ventricular Function in Discriminating Between Patients With Normal and Reduced Angiographic Ejection Fractions

	All Patients (no. = 110)		Patients With Coronary Disease (no. = 60)	
	EF \geq 55%	EF $<$ 55%	EF \geq 55%	EF $<$ 55%
EPSS				
<5 mm	66	6	28	3
\geq 5 mm	2	36	1	28
	$\chi^2 = 78.7^*$		$\chi^2 = 45.3^*$	
Echo EF				
\geq 65%	59	15	5	11
$<$ 65%	9	27	4	20
	$\chi^2 = 30.7^*$		$\chi^2 = 29.4^*$	
%S				
\geq 35	60	14	25	10
$<$ 35	8	28	4	21
	$\chi^2 = 35.5^*$		$\chi^2 = 32.8^*$	

* The chi square value for each four quadrant analysis is given. For all of these χ^2, P less than 0.001.

Echo EF = echocardiographic ejection fraction; EF = biplane angiographic ejection fraction; %S = percent shortening of the echographic minor axis.

function: Fairly good correlations were present between echographic and angiographic ejection fractions ($r = 0.73$, all patients; $r = 0.71$, patients with coronary disease) and between percent minor axis shortening and angiographic ejection fraction ($r = 0.72$, all patients; $r = 0.69$, patients with coronary disease). However, when the correlations between these two indexes and angiographic ejection fraction were compared with that between E point separation and angiographic ejection fraction for both patient groups, the latter was superior to each ($P < 0.025$).

Mitral-septal separation also proved to be more useful in discriminating between patients with normal and abnormal ventriculographic ejection fractions. If normal mitral-septal separation is defined as less than 5 mm, there were only two patients with a normal ejection fraction and increased mitral-septal separation, and only six with normal separation and a low ejection fraction (four of whom had an ejection fraction of 50 to 55 percent). Table II demonstrates that although each of the echographic indexes was useful in predicting which patients had a normal and which a low ejection fraction, mitral-septal separation was more reliable in separating these groups, particularly in the patients with coronary disease. This finding is especially noteworthy because the values for echographic ejection fraction and percent minor axis shortening (65 and 35 percent, respectively) chosen for this comparison were those that best separated the patients into those with a ventriculographic ejection fraction above or below 55 percent.

Discussion

Assessment of left ventricular function has become an important part of the echocardiographic examination.³ Angiographic ejection fraction has been demonstrated to be a useful measure of cardiac contractile

function^{1,2} and is an accepted standard for echocardiographic measurements of ventricular function. Our results, in agreement with those of others,⁴⁻⁸ indicate that there is a reasonably close correlation between echographic indexes of pump function and the angiographic ejection fraction in most patients. However, the decreased reliability of these unidimensional measurements in patients with segmental asynergy has been repeatedly demonstrated,¹⁰⁻¹³ and our lower overall correlation probably reflects the large number of patients with coronary artery disease in this series.

Our results indicate that the amount of mitral-septal separation in early diastole correlates well with ventriculographic ejection fraction in a large series of patients with a variety of cardiac diseases. This relation persists over a wide range of ventricular dimensions and ejection fractions. Mitral-septal separation appears to be invalid as an index of ventricular function only in patients with mitral stenosis or at least moderate aortic regurgitation.

The reliability of this index in patients with coronary artery disease is noteworthy. Although the index has some tendency to overestimate ejection fraction in patients with predominant apical-lateral synergy, and to underestimate it in those with anteroseptal asynergy, E point separation remains a generally applicable echographic index of ventricular function in the setting of ischemic heart disease. Further studies will be needed to determine the true frequency and magnitude of the discrepancies between the amount of mitral-septal separation and the ejection fraction in patients with segmental asynergy.

The utility of this variable is enhanced by the relative simplicity of obtaining simultaneous echoes from the anterior mitral leaflet and the interventricular septum at the required level without needing to define clearly the posterior wall endocardium. In addition, E point separation can be measured rapidly and no further computation is required, thus allowing a rapid estimation of ventricular function from an almost qualitative inspection of the echocardiogram.

Factors determining magnitude of mitral-septal separation: The relation of several indexes of mitral diastolic motion to blood flow, ventricular pressure and ventricular compliance has been investigated previously. However, no attempt has been made to relate systematically any aspect of diastolic mitral movement to a measure of systolic function such as ejection fraction. Hemodynamic variables affecting mitral valve motion in early diastole would be expected to have the most bearing on the magnitude of mitral-septal separation. Fischer et al.¹⁹ found a good correlation between an index of mitral valve diastolic opening and stroke volume, but others²⁰ have not been able to demonstrate a close relation between valve opening and blood flow experimentally. Decreases in anterior leaflet opening excursion (between the D and E points of its cycle) and in the rate of early diastolic opening have been described in patients with poor ventricular function or elevated initial diastolic pressure, respectively.^{14,21,22} In patients without mitral valve disease, the early diastolic closing velocity (E to F slope) of the mitral valve has also been

shown to correlate with transvalvular blood flow^{20,23} and to reflect alterations in indexes of the left ventricular pressure-volume relations.²³⁻²⁵

The magnitude of mitral-septal separation is determined by multiple geometric and hemodynamic factors, including the degree of mitral valve mobility, inter-ventricular septal motion, ventricular size and geometry and the pattern of early diastolic filling. If patients with conditions that restrict mitral valve mobility (such as mitral stenosis, congenital deformities of the mitral valve or aortic regurgitation) are excluded, this factor is probably not an important determinant in most patients. In the five patients with mitral valve prolapse, a condition that may be associated with the increased valve mobility, E point separation correlated well with ejection fraction.

Mitral-septal separation and abnormal septal motion: By defining the amount of mitral-septal separation as described, we have been able to measure it reproducibly in patients with abnormal septal motion. Four patients with paradoxical septal motion due to atrial septal defect had a normal ejection fraction and no E point separation. Because we have not studied other patients with paradoxical septal motion and right ventricular volume overload, with or without accompanying left ventricular failure, we are unable to comment on the reliability of this index in such patients. The one patient with paradoxical septal motion secondary to ischemic heart disease did manifest more mitral-septal separation than expected for the observed reduction in ejection fraction, and another patient with flat septal motion also displayed disproportionately increased separation. Thus, although this index continues to correlate well with ejection fraction in most patients with coronary artery disease and segmental anteroseptal asynergy, focal septal motion abnormalities will occasionally result in increased amounts of mitral-septal separation.

Mitral-septal separation, ventricular filling and ventricular size: Our data suggest that, although there is a weak correlation between ventricular size and the magnitude of mitral-septal separation, ventricular dimensions are not the sole determinant of the index. Rather, in most patients, mitral-septal separation probably reflects the interplay between early diastolic ventricular filling and ventricular size. Separation would thus increase as: (1) the ventricle enlarges without a proportional increment in early diastolic transmitral flow, or (2) the amount of early diastolic filling is reduced in a ventricle of a given size, either as a result of a decrease in overall stroke volume or in the fraction of filling occurring in early diastole. Recent evidence^{23,26,27} has demonstrated the decreased fraction of ventricular filling that occurs in early diastole in patients with coronary artery disease and other forms of heart disease. In patients with a mildly reduced ejection fraction in whom other echographic indexes of ventricular function remain normal, this shift of filling to later in diastole may be an early phenomenon and could explain the sensitivity of this index of ventricular function.

In conclusion, we have demonstrated that an easily performed measurement of the minimal separation

between the anterior mitral leaflet and the interventricular septum is a useful index of ventricular function. It correlates well with angiographic ejection fraction, regardless of chamber size, and appears to be useful in patients with coronary artery disease, in whom other echocardiographic indexes are less reliable.

Acknowledgment

We express our appreciation to Mrs. Gail Davis and Ms. Yin Yee for technical assistance, to Dr. Julien I. E. Hoffman for critical review of this manuscript, to Mrs. Kathleen Hecker for editorial assistance and to Mrs. Marilyn Baram for typing.

References

1. Cohn PF, Gorlin R: Dynamic ventriculography and the role of the ejection fraction. *Am J Cardiol* 36:529-531, 1975
2. Cohn PF, Gorlin R, Cohn LH, et al: Left ventricular ejection fraction as a prognostic guide in surgical treatment of coronary and valvular heart disease. *Am J Cardiol* 34:136-141, 1974
3. Feigenbaum H: Echocardiographic examination of the left ventricle. *Circulation* 51:1-7, 1975
4. Pombo JF, Troy BL, Russell RO: Left ventricular volumes and ejection fraction by echocardiography. *Circulation* 43:480-490, 1971
5. Fortuin NJ, Hood WP, Craige E: Evaluation of left ventricular function by echocardiography. *Circulation* 46:26-35, 1972
6. Gibson DG: Estimation of left ventricular size by echocardiography. *Br Heart J* 35:128-134, 1975
7. Ludbrook P, Karlner JS, Peterson K, et al: Comparison of ultrasound and cineangiographic measurements of left ventricular performance in patients with and without wall motion abnormalities. *Br Heart J* 35:1026-1032, 1973
8. Belenkie I, Nutter DO, Clark DW, et al: Assessment of left ventricular dimensions and function by echocardiography. *Am J Cardiol* 31:755-762, 1973
9. Cooper RH, O'Rourke RA, Karlner JS, et al: Comparison of ultrasound and cineangiographic measurements of the mean rate of circumferential fiber shortening in man. *Circulation* 46:914-923, 1972
10. Popp RL, Alderman EL, Brown OR, et al: Sources of error in calculation of left ventricular volumes by echocardiography (abstr). *Am J Cardiol* 31:152, 1973
11. Linhart JW, Mintz GS, Segal BL, et al: Left ventricular volume measurement by echocardiography: fact or fiction? *Am J Cardiol* 36:114-118, 1975
12. Teichholz LE, Kreulen T, Herman MV, et al: Problems in echocardiographic volume determinations: echocardiographic-angiographic correlations in the presence or absence of asynergy. *Am J Cardiol* 37:7-11, 1975
13. Henning H, Schelbert H, Crawford MH, et al: Left ventricular performance assessed by radionuclide angiography and echocardiography in patients with previous myocardial infarction. *Circulation* 52:1069-1075, 1975
14. Burgess J, Clark R, Kamaki M, et al: Echocardiographic findings in different types of mitral regurgitation. *Circulation* 48:97-106, 1973
15. Strunk BL, Guss SB, Hicks RE, et al: Echocardiographic recognition of the mitral valve-posterior aortic wall relationship. *Circulation* 51:594-598, 1975
16. Shah PM, Gramiak R, Kramer OH: Ultrasound localization of left ventricular outflow obstruction in hypertrophic obstructive cardiomyopathy. *Circulation* 40:3-11, 1969
17. Goerke RJ, Carlsson E: Calculation of right and left ventricular volumes. Methods using standard computer equipment and biplane angiograms. *Invest Radiol* 2:360-367, 1967
18. Botvinick EH, Schiller NB, Wickramasekaran R, et al: Echocardiographic demonstration of early mitral valve closure in severe aortic insufficiency. *Circulation* 51:836-847, 1975
19. Fischer JC, Chang S, Konecke LL, et al: Echocardiographic determination of mitral valve flow (abstr). *Am J Cardiol* 29:282, 1972
20. Laniado S, Yellin E, Kotler M, et al: A study of the dynamic relations between the mitral valve echogram and phasic mitral flow. *Circulation* 51:104-113, 1973
21. Millward DK, McLaurin LP, Craige E: Echocardiographic studies of the mitral valve motion in patients with congestive cardiomyopathy and mitral regurgitation. *Am Heart J* 85:413-431, 1973
22. Konecke LL, Feigenbaum H, Chang S, et al: Abnormal mitral valve motion in patients with elevated left ventricular diastolic pressures. *Circulation* 47:989-996, 1973
23. DeMaria AN, Miller RR, Amsterdam EA, et al: Mitral valve early diastolic closing velocity in the echocardiogram: relationship to sequential diastolic flow and ventricular compliance. *Am J Cardiol* 37:693-700, 1976
24. Layton C, Gent G, Priddle R, et al: Diastolic closure rate of normal mitral valve. *Br Heart J* 35:1066-1074, 1973
25. Quinones MA, Gaasch WH, Walser E, et al: Reduction in the rate of diastolic descent of the mitral valve echogram in patients with altered left ventricular diastolic pressure-volume relations. *Circulation* 49:246-254, 1974.
26. Silverman B, Fortuin N: Diastolic filling in cardiac disease (abstr). *Clin Res* 20:398, 1972
27. Decoodt PR, Mathey DG, Swan HJC: Abnormal left ventricular filling in coronary artery disease (abstr). *Circulation* 52:Suppl II:113, 1975