



Ropivacaine for ultrasound-guided interscalene block: 5 mL provides similar analgesia but less phrenic nerve paralysis than 10 mL

La ropivacaine pour les blocs interscaléniques par échoguidage: une dose de 5 mL fournit une analgésie semblable mais moins de paralysie du nerf phrénique qu'une dose de 10 mL

Joon-Ho Lee, MD, PhD · Sung-Hwan Cho, MD · Sang-Hyun Kim, MD, PhD ·
Won-Soek Chae, MD, PhD · Hee-Cheol Jin, MD, PhD · Jeong-Seok Lee, MD, PhD ·
Yong-Ik Kim, MD, PhD

Received: 18 February 2011 / Accepted: 27 July 2011 / Published online: 20 August 2011
© Canadian Anesthesiologists' Society 2011

Abstract

Purpose Interscalene brachial plexus block (interscalene block) complications usually depend on the dose administered. The objective of this study was to determine whether ultrasound-guided interscalene block with a 5-mL dose of 0.75% ropivacaine would have sufficient analgesic efficacy after shoulder arthroscopic surgery when compared with a 10-mL dose.

Methods Patients undergoing arthroscopic rotator cuff repair surgery ($n = 60$) were assigned randomly to one of two groups receiving 5 mL (Group 5) or 10 mL (Group 10) of 0.75% ropivacaine. Ultrasound-guided interscalene block was performed using the in-plane technique, and general anesthesia was administered. Time to first analgesic request was recorded, and the following issues were assessed in the postanesthesia care unit at six, 12, 24, and 48 hr postoperatively: postoperative pain as determined by a visual analogue scale (VAS), patient satisfaction, hemidiaphragmatic paralysis, other block-related complications, and postoperative nausea and vomiting (PONV).

Results There was no significant difference between groups in time to first analgesic requirement (median [interquartile range] for Group 5: 16 [12–48] hr, Group 10: 18 [12–48] hr; $P = 0.907$). The postoperative pain VAS score was similar in both groups. The incidence of hemidiaphragmatic paralysis on postoperative chest x-ray was 33% in Group 5 and 60% in Group 10 ($P = 0.035$). However, the incidences of other block-related complications, PONV, and patient satisfaction were not significantly different between groups.

Conclusion Interscalene block performed under ultrasound guidance with 0.75% ropivacaine 5 mL showed analgesic efficacy similar to that with 0.75% ropivacaine 10 mL, but with a lower incidence of hemidiaphragmatic paralysis.

Résumé

Objectif Les complications liées aux blocs interscaléniques du plexus brachial (blocs interscaléniques) dépendent en général de la dose administrée. L'objectif de cette étude était de déterminer si les blocs interscaléniques par échoguidage réalisés avec une dose de 5 mL de ropivacaine 0,75 % auraient une efficacité analgésique suffisante après une arthroscopie de l'épaule par rapport à ceux réalisés avec une dose de 10 mL.

Méthode Des patients subissant une réparation arthroscopique de la coiffe des rotateurs ($n = 60$) ont été randomisés à l'un de deux groupes, soit à recevoir 5 mL (groupe 5) ou 10 mL (groupe 10) de ropivacaine 0,75 %. Un bloc interscalénique par échoguidage a été réalisé à l'aide d'une technique d'insertion de l'aiguille 'en plan', et une

J.-H. Lee, MD, PhD (✉) · S.-H. Cho, MD ·
S.-H. Kim, MD, PhD · W.-S. Chae, MD, PhD ·
H.-C. Jin, MD, PhD · J.-S. Lee, MD, PhD · Y.-I. Kim, MD, PhD
Department of Anesthesiology and Pain Medicine, Bucheon
Hospital, University of Soonchunhyang, 1174 Jung-Dong,
Wonmi-Gu, Bucheon-Si, Gyeonggi-Do 420-767, Korea
e-mail: anpjuno@gmail.com

anesthésie générale a été administrée. Le temps jusqu'à la première demande d'analgésiques a été enregistré, et les éléments suivants ont été évalués en salle de réveil à six, 12, 24 et 48 h postopératoires: douleur postopératoire telle que déterminée par une échelle visuelle analogique (EVA), satisfaction du patient, paralysie hémi-diaphragmatique, autres complications liées au bloc, et nausées et vomissements postopératoires (NVPO).

Résultats Aucune différence significative n'a été observée entre les groupes quant au temps jusqu'à la première demande d'analgésiques (médiane [écart interquartile] pour le groupe 5: 16 [12-48] h, groupe 10: 18 [12-48] h; $P = 0,907$). Le score de douleur postopératoire sur l'EVA était semblable dans les deux groupes. L'incidence de paralysie hémi-diaphragmatique à la radiographie postopératoire des poumons était de 33 % dans le groupe 5 et de 60 % dans le groupe 10 ($P = 0,035$). Les incidences d'autres complications liées au bloc, de NVPO et la satisfaction des patients n'étaient toutefois pas significativement différentes entre les groupes.

Conclusion Les blocs interscaléniques réalisés sous échoguidage avec 5 mL de ropivacaïne 0,75 % ont montré une efficacité analgésique semblable à 10 mL de ropivacaïne 0,75 %, mais une incidence moindre de paralysie hémi-diaphragmatique.

Interscalene brachial plexus block (interscalene block) is regarded as an effective anesthetic and analgesic method for arthroscopic shoulder surgery.¹ It can reduce the requirement for systemic analgesia after surgery and thus minimize related complications.² However, the standard interscalene block technique requires large volumes of local anesthetics to achieve acceptable success rates.³ Thus, possible complications may occur due to the injection of such large amounts of local anesthetics, including hemodynamic, respiratory, and central nervous system impairment.²

Ultrasound guidance for interscalene block is becoming increasingly common, and it can maximize block quality while minimizing block-related complications by injection under direct visualization of the target nerve.^{4,5} The focus of previous investigations regarding the analgesic efficacy of low volumes of local anesthetics performed under ultrasound guidance has been more on reducing the incidence of complications rather than on the quality of analgesia.^{6,7}

In this prospective randomized double-blind study, we hypothesized that ultrasound-guided interscalene block with 0.75% ropivacaine 5 mL could produce analgesic efficacy equivalent to that of 0.75% ropivacaine 10 mL after arthroscopic rotator cuff repair surgery with general anesthesia. Time to first analgesic request, postoperative

pain, postoperative nausea and vomiting (PONV), hemidiaphragmatic paralysis, and other block-related complications as well as patient satisfaction were assessed.

Methods

Subjects

This study was conducted with approval of the Institutional Review Board of the Soonchunhyang University Bucheon Hospital (SCHBC_IRB_10_40) and in accordance with the Declaration of Helsinki. Written informed consent was obtained from each patient before enrolment in the study.

Sixty-two patients (ages 18-70 yr, American Society of Anesthesiologists' physical status I and II) scheduled to undergo arthroscopic rotator cuff repair surgery were enrolled in the study. Exclusion criteria included a history of allergic or anaphylactic reaction to local anesthetics, pre-existing chronic obstructive pulmonary disease, renal or hepatic impairment, clinically relevant abnormal electrocardiogram (ECG), active infection at the planned injection site, coagulopathy, body mass index $> 35 \text{ kg} \cdot \text{m}^{-2}$, pregnancy or lactation, history of drug abuse or psychosis, currently taking pain medication, pre-existing motor or sensory deficit, and patient refusal. On the day before surgery, the patients were randomly assigned using a computer-generated sequence to receive interscalene block with either 5 mL (Group 5) or 10 mL (Group 10) of 0.75% ropivacaine.

Ultrasound-guided interscalene brachial plexus block

After the intravenous route was secured in the contralateral forearm, routine monitors (ECG, noninvasive blood pressure, pulse oximetry) were applied. Patients were placed in the supine position with the neck rotated slightly to the contralateral side. The skin was prepared in typical sterile fashion. An interscalene block was performed using an M-Turbo[®] ultrasound system (SonoSite, Bothell, WA, USA) with a 13-6 MHz 38-mm high-frequency linear array transducer (HFL38x; SonoSite). The transducer was covered with a sterile adhesive bandage (Tegaderm[®], 3 M Health Care, St. Paul, MN, USA).

A transverse scan was performed at the level of the interscalene groove, with the long axis of the probe parallel to the clavicle. The transducer was then moved slightly in the caudal direction until brachial plexus roots were identified. After the transducer position was confirmed, 1% mepivacaine was applied under the skin to form a wheal, and a 25G 1.5-inch bevelled needle was inserted on the lateral side of the transducer using the in-plane technique. Extension tubing was connected between the needle and a

20-mL syringe filled with 0.75% ropivacaine. The final target position of the needle was immediately posterior to the space between the C5 and C6 roots. When needle placement was confirmed, 5 or 10 mL of 0.75% ropivacaine were injected carefully with intermittent aspiration. All blocks were performed under ultrasound guidance alone and by the same attending anesthesiologist who was experienced in ultrasound-guided regional anesthesia.

Block assessment

Blockade was evaluated by a clinician who was blinded to the volume of the injectate. After completion of the block, motor and sensory blockades were assessed every five minutes for up to 30 min. Motor blockade was determined by loss of shoulder abduction (deltoid sign),⁸ and sensory blockade was assessed using a pinprick and alcohol sponge in the C5-7 dermatome. Failure to lose shoulder abduction until 30 min after interscalene block was considered as block failure. Immediate complications, such as hematoma formation, Horner's syndrome, hoarseness, respiratory distress, and spinal/epidural injection, were also assessed during this period.

Intraoperative management

After confirmation of a successful blockade, general anesthesia was induced with propofol 1.5–2.0 mg·kg⁻¹ and fentanyl 1.0 µg·kg⁻¹. The bispectral index (BIS) was monitored. Rocuronium 0.6 mg·kg⁻¹ was given to facilitate endotracheal intubation. The lungs were ventilated with a mixture of oxygen and air (inspired O₂ fraction: 0.4), and desflurane was titrated to maintain a BIS value of 40–60. Minute ventilation was adjusted to maintain normocapnia. For surgery, the patient was placed in the lateral decubitus position. No opioid or analgesic drugs were administered during maintenance of anesthesia unless mean arterial blood pressure or heart rate increased 20% above preoperative baseline values, in which case, fentanyl 0.5 µg·kg⁻¹ was administered. No additional local anesthetic infiltration was performed during surgery. At the end of surgery, patients received ondansetron 4 mg *iv*, and residual paralysis was antagonized with intravenous neostigmine 40 µg·kg⁻¹ and glycopyrrolate 7 µg·kg⁻¹.

Measurement

After tracheal extubation, the patients were transferred to the postanesthesia care unit (PACU). When they were stable, oriented, and had obtained a score > 9 on the modified Aldrete scale, a blinded observer performed the following assessments: a) pain intensity, measured on a 100-mm visual analogue scale (VAS), ranging from 0 (no

pain) to 100 (worst pain imaginable); b) PONV; c) presence of hemidiaphragmatic paralysis, by comparison of pre- and postoperative chest *x-rays*; and d) presence of other complications associated with interscalene block, including hematoma formation, Horner's syndrome, hoarseness, respiratory distress, neurological complications, spinal/epidural injection, and infection. All of these parameters were assessed in the PACU and at six, 12, 24, and 48 hr postoperatively. The time from the end of the injection of local anesthetic to first analgesic request and patient satisfaction were also assessed during the 48-hr follow-up period. Hemidiaphragmatic paralysis was defined as the elevation of the diaphragm > 4 cm above its preoperative position.⁹ All patients received tramadol hydrochloride 50 mg·mL⁻¹ (Tridol®, Yu-Han Inc., Seoul, Korea) *im* for breakthrough pain during the follow-up period. Patient satisfaction was rated on a five-point Likert scale: 1, bad; 2, poor; 3, fair; 4, good; and 5, excellent.

Sample size estimation

The primary outcome variable was the time to first analgesic request. The secondary outcome variables were postoperative VAS pain score and incidences of hemidiaphragmatic paralysis, PONV, and other block-related complications. Based on our pilot study, the time to first analgesic request with 10 mL of 0.75% ropivacaine was estimated to be approximately 13 hr, and we considered a 30% difference in time to be clinically significant. Assuming a standard deviation of 1.4 hr, the sample size was determined based on proportions using a two-sided Student's *t* test. Accepting a type I error rate of 0.05 and a type II error rate of 0.20 (power of 80%), 28 patients were required in each group. We planned to recruit 62 patients for the study to account for dropouts.

Statistical analysis

Quantitative data are presented as means with standard deviation (SD) or medians with range or interquartile range [IQR], and qualitative data are presented as frequency or numbers of patients with percent. Numerical variables were examined for normality. Demographic data were analyzed using Student's *t* test and the χ^2 test, and time to first analgesic request was analyzed by Kaplan-Meier survival analysis, with a comparison between groups using the log-rank test. Survival time was defined as the time from the end of the interscalene block to the first rescue analgesia. Postoperative pain and patient satisfaction scores were analyzed using the Mann-Whitney U test, and incidences of PONV and block-related complications, including hemidiaphragmatic paralysis, were analyzed by Fisher's exact test. All data were analyzed using SPSS® software version

14.0 (SPSS, Inc., Chicago, IL, USA), and survival curves were plotted using Prism 5.0 for Windows (GraphPad Software, Inc., San Diego, CA, USA). In all analyses, $P < 0.05$ was taken to indicate statistical significance.

Results

Thirty-one patients were recruited in each group, and 30 patients in each group remained for analysis. Two patients were excluded—one in Group 5 because of incomplete postoperative data and one in Group 10 because analgesics other than the study drug were administered in the postoperative period. The groups were similar with respect to age, sex, weight, height, American Society of Anesthesiologists (ASA) classification, or the duration of anesthesia or operation (Table 1).

Median [IQR] times to first analgesic request were similar in both groups (16 [12–48] hr in Group 5 and 18 [12–48] hr in Group 10; $P = 0.907$). The results of Kaplan-Meier analysis are shown in Figure. There was no significant difference between groups with respect to the number of patients not requiring rescue analgesia for pain ($n = 12$ in both groups) or the quantity of tramadol doses required (35(32) mg vs 37 (36) mg; $P = 0.75$).

Postoperative pain scores (VAS) in both groups are shown in Table 2. Pain scores were similar in both groups.

The incidence of hemidiaphragmatic paralysis on postoperative chest *x-rays* was significantly greater in Group 10 ($P = 0.035$). The amount of intraoperative fentanyl used, the incidence of PONV and other block-related complications, and patient satisfaction scores did not differ significantly between groups (Table 3). None of the patients received fentanyl during the operation apart from the induction period.

Most of the complications attributed to interscalene block observed during the follow-up period were neurological, including prolonged paresthesia or numbness. One

Table 1 Patient characteristics and operative data. Values are presented as means (SD) or number of patients

	Group 5	Group 10
Number of patients	30	30
Age (yr)	55.6 (6.0)	54.7 (9.7)
Gender (male/female)	11/19	10/20
Weight (kg)	64.7 (12.2)	63.0 (10.4)
Height (cm)	160.0 (12.0)	160.4 (9.5)
ASA classification (I/II)	13/17	17/13
Operation time (min)	98 (35)	94 (39)
Anesthesia time (min)	151 (36)	150 (43)

ASA = American Society of Anesthesiologists

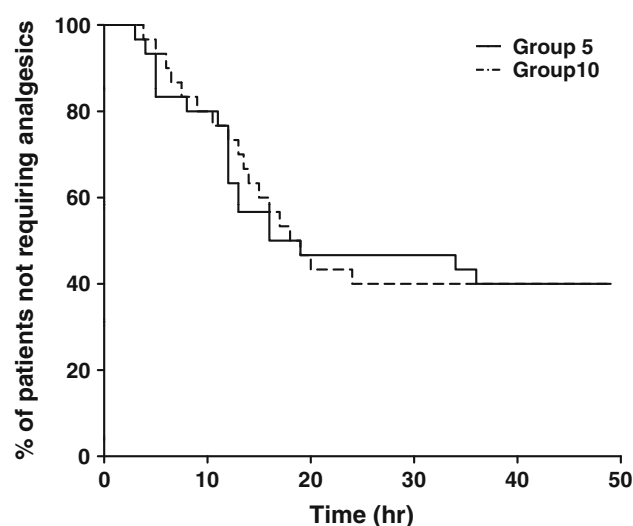


Figure Proportion of patients not requiring analgesics in relation to time after block in the groups receiving 5 mL (Group 5) and 10 mL (Group 10) of 0.75% ropivacaine. There was no significant difference between groups ($P = 0.907$, log-rank test)

Table 2 Median postoperative pain scores during follow-up period (100 mm visual analogue scale)

	Group 5	Group 10
PACU	0 (0–20)	0 (0–20)
Postop 6 hr	10 (0–30)	0 (0–35)
Postop 12 hr	20 (0–35)	10 (0–35)
Postop 24 hr	20 (0–50)	20 (0–45)
Postop 48 hr	15 (0–40)	20 (0–40)

Values are presented as median (range). PACU = postanesthesia care unit. Pain scores were similar in both groups

Table 3 Incidence of PONV, hemidiaphragmatic paralysis, other block-related complications and patient satisfaction score

	Group 5	Group 10
PONV (%)	2 (6.7)	1 (3.3)
Hemidiaphragmatic paralysis (%)	10 (33)	18 (60)*
Complications (%)	2 (6.7)	4 (13.3)
Satisfaction score	4 (3–5)	4 (3–5)

Values are presented as numbers (%) or median (range). Group 5: the patients received interscalene block with 5 mL 0.75% ropivacaine; Group 10: the patients received interscalene block with 10 mL 0.75% ropivacaine; PONV = postoperative nausea and vomiting. * $P < 0.05$ compared with Group 5

patient complained of prolonged paresthesia in the thumb and index finger lasting about 12 hr. Two patients complained of prolonged numbness. One reported numbness of the distal phalanx of the index finger which lasted longer than 14 hr, and the other complained of numbness in the index and middle finger which lasted approximately 12 hr.

All of the symptoms disappeared during the follow-up period.

Discussion

The results of the present study indicate that interscalene block under ultrasound guidance with 5 mL of 0.75% ropivacaine provides a quality of analgesia similar to that with 10 mL of 0.75% ropivacaine after arthroscopic rotator cuff repair surgery. The incidence of hemidiaphragmatic paralysis on postoperative chest *x-rays* was significantly higher in Group 10. However, there was no significant difference between groups in the time to first analgesic request or the incidence of other block-related complications. Patient satisfaction and PONV also showed no significant differences between groups.

Although arthroscopic surgery is considered minimally invasive, pain following arthroscopic shoulder surgery is often moderate to severe and can require large amounts of opioid analgesics.¹⁰ Adequate postoperative pain control is important for the successful outcome of orthopedic surgery in terms of early rehabilitation, mobilization, and functional recovery.¹¹ Various techniques, including single and/or continuous interscalene block, suprascapular nerve block, intra-articular analgesia, and surgical wound infiltration, have been introduced to reduce postoperative pain after arthroscopic shoulder surgery.^{12,13} Among these modalities, interscalene block is the technique used most commonly for postoperative analgesia. However, single-shot interscalene block may not provide a sufficient duration of effective analgesia following shoulder surgery, and complementary continuous interscalene block is often needed.

In our study, a single-injection interscalene block under ultrasound guidance provided sufficient analgesia, even with a low volume of local anesthetic, during the first 48 hr postoperatively. However, previous investigations demonstrated that large amounts of analgesic were required after shoulder arthroscopic surgery, even after brachial plexus block was performed.^{1,6,7,13,14} We cannot explain this discrepancy completely, but this may be an ethnic difference in pain behavior. Although debatable, Asian patients tend to require fewer analgesics during the postoperative period regardless of the intensity of their pain,^{15,16} which may possibly explain why our patients require less analgesic medication than previously reported.

Ultrasound not only facilitates imaging of the nerve plexus and adjacent anatomical structures, but it also permits the accurate deposition of local anesthetics near the target nerve under dynamic visualization of the needle.¹⁷ The use of ultrasound in peripheral nerve block allows a relatively small volume of anesthetic to produce successful

blockade and therefore reduce complications, which are usually dose-related.^{6,17-19} In this study, we showed that the incidence of hemidiaphragmatic paralysis on postoperative chest *x-rays* was significantly lower in Group 5 compared with Group 10. Previous investigations have indicated a 100% incidence of ipsilateral hemidiaphragmatic paralysis after interscalene block.^{20,21} Thus, the ability to reduce the incidence of hemidiaphragmatic paralysis by using a small volume of local anesthetic for interscalene block is important.

This study had several limitations. First, the physician performing the blocks was not blinded to the group assignment because the spread of the local anesthetic must be observed directly on the screen of the ultrasound machine. Second, we did not investigate the duration of motor and sensory block. However, this was not the aim of the present study, and precise assessments of motor and sensory functions were nearly impossible because of the dressings and abduction brace used. Finally, we performed no objective assessment of postoperative respiratory function, such as a spirometry or an ultrasonographic examination of diaphragmatic movement. The postoperative respiratory assessments based on the chest radiography and the patients' subjective symptoms do not necessarily reflect the relationship between the reduction of local anesthetics and the lower incidence of hemidiaphragmatic paralysis. However, these assessments are easier to perform under clinical conditions. The true incidence of hemidiaphragmatic paresis may be higher than indicated here.

In conclusion, when combined with general anesthesia, ultrasound-guided interscalene block with 5 mL of 0.75% ropivacaine showed an analgesic effect similar to that of 10 mL of the same drug after arthroscopic shoulder surgery. The incidence of hemidiaphragmatic paralysis on postoperative *x-rays* was significantly lower in the low-volume group, and the incidences of other complications related to the interscalene block as well as patient satisfaction with regard to postoperative pain management were similar between the 5-mL and 10-mL groups. Ultrasound-guided interscalene block with 5 mL of 0.75% ropivacaine has the advantage of a reduced incidence of hemidiaphragmatic paralysis while providing a degree of analgesia similar to that with 10 mL of the same agent.

Funding This study was supported solely from institutional and departmental sources.

Conflicts of Interest None declared.

References

1. Singelyn FJ, Lhotel L, Fabre B. Pain relief after arthroscopic shoulder surgery: a comparison of intraarticular analgesia,

- suprascapular nerve block, and interscalene brachial plexus block. *Anesth Analg* 2004; 99: 589-92.
2. Long TR, Wass CT, Burkle CM. Perioperative interscalene blockade: an overview of its history and current clinical use. *J Clin Anesth* 2002; 14: 546-56.
3. Winnie AP. Interscalene brachial plexus block. *Anesth Analg* 1970; 49: 455-66.
4. Marhofer P, Greher M, Kapral S. Ultrasound guidance in regional anaesthesia. *Br J Anaesth* 2005; 94: 7-17.
5. Kapral S, Greher M, Huber G, et al. Ultrasonographic guidance improves the success rate of interscalene brachial plexus blockade. *Reg Anesth Pain Med* 2008; 33: 253-8.
6. Riaz S, Carmichael N, Awad I, Holby RM, McCartney CJ. Effect of local anaesthetic volume (20 vs 5 ml) on the efficacy and respiratory consequences of ultrasound-guided interscalene brachial plexus block. *Br J Anaesth* 2008; 101: 549-56.
7. Renes SH, Rettig HC, Gielen MJ, Wilder-Smith OH, van Geffen GJ. Ultrasound-guided low-dose interscalene brachial plexus block reduces the incidence of hemidiaphragmatic paresis. *Reg Anesth Pain Med* 2009; 34: 498-502.
8. Wiener DN, Speer KP. The deltoid sign. *Anesth Analg* 1994; 79: 192.
9. Freedman B. Unilateral paralysis of the diaphragm and larynx associated with inflammatory lung disease. *Thorax* 1950; 5: 169-82.
10. Al-Kaisy A, McGuire G, Chan VW, et al. Analgesic effect of interscalene block using low-dose bupivacaine for outpatient arthroscopic shoulder surgery. *Reg Anesth Pain Med* 1998; 23: 469-73.
11. Capdevila X, Barthelet Y, Biboulet P, Ryckwaert Y, Rubenovitch J, d'Athis F. Effects of perioperative analgesic technique on the surgical outcome and duration of rehabilitation after major knee surgery. *Anesthesiology* 1999; 91: 8-15.
12. Rawal N, Axelsson K, Hylander J, et al. Postoperative patient-controlled local anesthetic administration at home. *Anesth Analg* 1998; 86: 86-9.
13. Beaudet V, Williams SR, Tetreault P, Perrault MA. Perioperative interscalene block versus intra-articular injection of local anesthetics for postoperative analgesia in shoulder surgery. *Reg Anesth Pain Med* 2008; 33: 134-8.
14. Borgeat A, Schappi B, Biasca N, Gerber C. Patient-controlled analgesia after major shoulder surgery: patient-controlled interscalene analgesia versus patient-controlled analgesia. *Anesthesiology* 1997; 87: 1343-7.
15. Houghton IT, Aun CS, Gin T, Lau JT. Inter-ethnic differences in postoperative pethidine requirements. *Anaesth Intensive Care* 1992; 20: 52-5.
16. Lee A, Gin T, Oh TE. Opioid requirements and responses in Asians. *Anaesth Intensive Care* 1997; 25: 665-70.
17. Marhofer P, Chan VW. Ultrasound-guided regional anesthesia: current concepts and future trends. *Anesth Analg* 2007; 104: 1265-9.
18. O'Donnell BD, Iohom G. An estimation of the minimum effective anesthetic volume of 2% lidocaine in ultrasound-guided axillary brachial plexus block. *Anesthesiology* 2009; 111: 25-9.
19. Willschke H, Marhofer P, Bosenberg A, et al. Ultrasonography for ilioinguinal/iliohypogastric nerve blocks in children. *Br J Anaesth* 2005; 95: 226-30.
20. Urmey WF, Talts KH, Sharrock NE. One hundred percent incidence of hemidiaphragmatic paresis associated with interscalene brachial plexus anesthesia as diagnosed by ultrasonography. *Anesth Analg* 1991; 72: 498-503.
21. Urmey WF, McDonald M. Hemidiaphragmatic paresis during interscalene brachial plexus block: effects on pulmonary function and chest wall mechanics. *Anesth Analg* 1992; 74: 352-7.