

Quick Case

Starr Knight
ED Faculty Meeting
July 14, 2015

Visit #1

- 22 y/o F G3P2 at 6weeks by LMP with vaginal bleeding and abd pain.

T: 36.9 BP: 105/73 HR: 92 RR: 20 O2: 99%

Bedside U/S

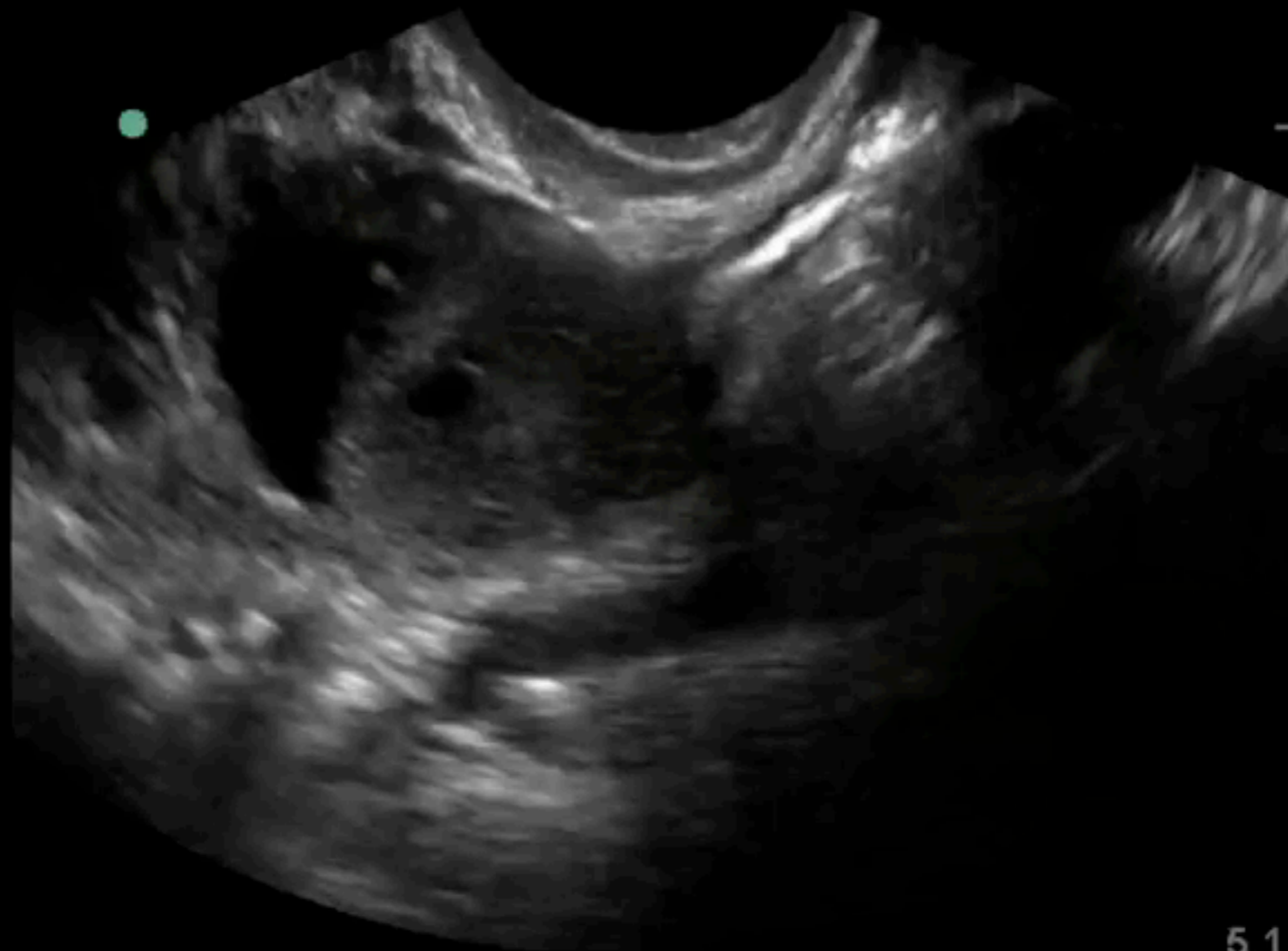RODAS CARDONA, W.

01909315

2015Jun22 03:50

Gen
S MB

Gyn
ICT




96%

MI

0.5

TIS

0.1



5.1

Bedside U/S

Bedside U/S

Bedside U/S

Visit #1

- IUP
- PMD f/u for BHCG Trending and Formal U/S
- D/C'd Home

Visit #2

(5 Days Later)

- 22 F G2P3 at 7wks vaginal spotting & pelvic pain
- NP Provider
- Gyn C/S
- Formal U/S- No IUP
 - ?cystic structure adjacent to C-sec Scar
 - Gyn to f/u with serial BHCG & U/S

Visit #3

(7 Days Later)

- 22 F G3P2 at 7 weeks, Formal U/S 2 days ago with no IUP here c/o vaginal spotting & abd pain

Bedside U/S

Guide to TV

- Interrogate the Uterus in 2 Planes
- Interrogate the Adnexa
- If no IUP seen include RUQ view
- Full Bladder for Transabdominal Scans
- Empty Bladder for Transvaginal Scans

Interrogate the Uterus

Interrogate the Uterus

Interrogate the Adnexa

Interrogate the Uterus

Common Pitfalls

Visit #3

(7 Days Later)

- Formal U/S shows L tubal ectopic
- Pt tx'd with MTX
- Serial down trending HCGs
- Good Outcome

Take Home

- Interrogate the Uterus (in at least 2 planes)
- Interrogate the adnexa
- If no IUP seen arrange for Gyn f/u or formal imaging prior to d/c

Happy Scanning